

GUIDELINES AND STANDARDS

Echocardiographic Assessment of Valve Stenosis: EAE/ASE Recommendations for Clinical Practice

Helmut Baumgartner, MD,[†] Judy Hung, MD,[‡] Javier Bermejo, MD, PhD,[†]
John B. Chambers, MD,[†] Arturo Evangelista, MD,[†] Brian P. Griffin, MD,[‡] Bernard Iung, MD,[†]
Catherine M. Otto, MD,[‡] Patricia A. Pellikka, MD,[‡] and Miguel Quiñones, MD[‡]

Abbreviations: AR = aortic regurgitation, AS = aortic stenosis, AVA = aortic valve area, CSA = cross sectional area, CWD = continuous wave Doppler, D = diameter, HOCM = hypertrophic obstructive cardiomyopathy, LV = left ventricle, LVOT = left ventricular outflow tract, MR = mitral regurgitation, MS = mitral stenosis, MVA = mitral valve area, DP = pressure gradient, RV = right ventricle, RVOT = right ventricular outflow tract, SV = stroke volume, TEE = transesophageal echocardiography, $T_{1/2}$ = pressure half-time, TR = tricuspid regurgitation, TS = tricuspid stenosis, V = velocity, VSD = ventricular septal defect, VTI = velocity time integral

Continuing Medical Education Activity for "Echocardiographic Assessment of Valve Stenosis: EAE/ASE Recommendations for Clinical Practice"

Accreditation Statement:

The American Society of Echocardiography is accredited by the Accreditation Council for Continuing Medical Education to provide continuing medical education for physicians. The American Society of Echocardiography designates this educational activity for a maximum of 1 AMA PRA Category 1 Credit™. Physicians should only claim credit commensurate with the extent of their participation in the activity.

ARDMS and CCI recognize ASE's certificates and have agreed to honor the credit hours toward their registry requirements for sonographers.

The American Society of Echocardiography is committed to resolving all conflict of interest issues, and its mandate is to retain only those speakers with financial interests that can be reconciled with the goals and educational integrity of the educational program. Disclosure of faculty and commercial support sponsor relationships, if any, have been indicated.

Target Audience:

This activity is designed for all cardiovascular physicians, cardiac sonographers and nurses with a primary interest and knowledge base in the field of echocardiography; in addition, residents, researchers, clinicians, sonographers, and other medical professionals having a specific interest in valvular heart disease may be included.

Objectives:

Upon completing this activity, participants will be able to: 1. Demonstrate an increased knowledge of the applications for echocardiographic assessment of valvular stenosis and their impact on cardiac diagnosis. 2. Differentiate the different methods for echocardiographic assessment of valvular stenosis. 3. Recognize the criteria for echocardiographic grading of valvular stenosis. 4. Identify the advantages and disadvantages of the methodologies employed for assessing valvular stenosis and apply the most appropriate methodology in clinical situations. 5. Incorporate the echocardiographic methods of valvular stenosis to form an integrative approach to assessment of valvular stenosis. 6. Effectively use echocardiographic assessment of valvular stenosis for the diagnosis and therapy for significant valvular stenosis. 7. Assess the common pitfalls in echocardiographic assessment of valvular stenosis and employ appropriate standards for consistency of valvular stenosis assessment.

Author Disclosures:

Bernard Iung: Speaker's Fee – Edwards Lifesciences, Sanofi-Aventis.

The following stated no disclosures: Helmut Baumgartner, Judy Hung, Javier Bermejo, John B. Chambers, Arturo Evangelista, Brian P. Griffin, Catherine M. Otto, Patricia A. Pellikka, Miguel Quiñones.

Conflict of interest: The authors have no conflicts of interest to disclose except as noted above.

Estimated Time to Complete This Activity: 1 hour

I. INTRODUCTION

Valve stenosis is a common heart disorder and an important cause of cardiovascular morbidity and mortality. Echocardiography has become the key tool for the diagnosis and evaluation of valve disease, and is the primary non-invasive imaging method for valve stenosis assessment. Clinical decision-making is based on echocardiographic assessment of the severity of valve stenosis, so it is essential that standards be adopted to maintain accuracy and consistency across echocardiographic laboratories when assessing and reporting valve stenosis. The aim of this paper was to detail the recommended approach to the echocardiographic evaluation of valve stenosis, including recommendations for specific measures of stenosis severity, details of data acquisition and measurement, and grading of severity. These recommendations are based on the scientific literature and on the consensus of a panel of experts.

This document discusses a number of proposed methods for evaluation of stenosis severity. On the basis of a comprehensive literature review and expert consensus, these methods were categorized for clinical practice as:

- Level 1 Recommendation: an appropriate and recommended method for all patients with stenosis of that valve.
- Level 2 Recommendation: a reasonable method for clinical use when additional information is needed in selected patients.
- Level 3 Recommendation: a method not recommended for routine clinical practice although it may be appropriate for research applications and in rare clinical cases.

It is essential in clinical practice to use an integrative approach when

From the University of Muenster, Muenster, Germany (H.B.); Massachusetts General Hospital, Boston, MA, USA (J.H.); Hospital General Universitario Gregorio Marañón, Barcelona, Spain (J.B.); Huy's and St. Thomas' Hospital, London, United Kingdom (J.B.C.); Hospital Vall D'Hebron, Barcelona, Spain (A.E.); Cleveland Clinic, Cleveland, OH, USA (B.P.G.); Paris VII Denis Diderot University, Paris, France (B.I.); University of Washington, Seattle, WA, USA (C.M.O.); Mayo Clinic, Rochester, MN, USA (P.A.P.); and The Methodist Hospital, Houston, TX, USA (M.Q.)

Reprint requests: American Society of Echocardiography, 2100 Gateway Centre Boulevard, Suite 310, Morrisville, NC 27560, ase@asecho.org.

[†] Writing Committee of the European Association of Echocardiography (EAE).

[‡] American Society of Echocardiography (ASE).

0894-7317/\$36.00

Republished with permission from the European Society of Cardiology. © The Author 2008.

doi:10.1016/j.echo.2008.11.029

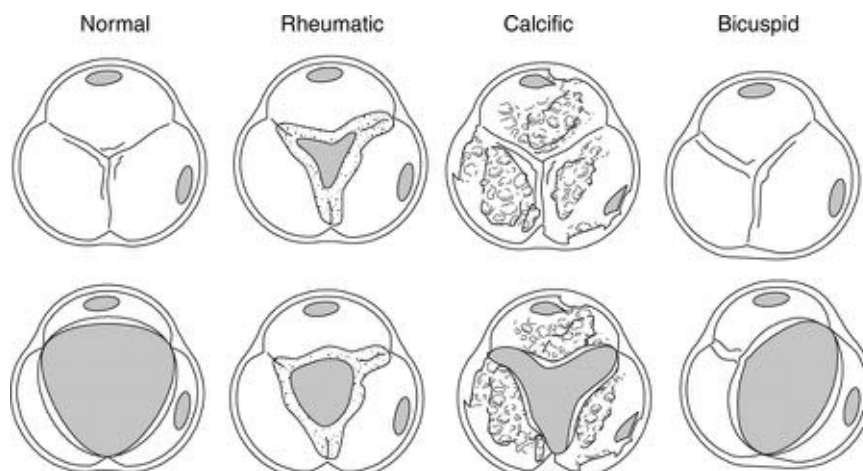


Figure 1 Aortic stenosis aetiology: morphology of calcific AS, bicuspid valve, and rheumatic AS (Adapted from C. Otto, *Principles of Echocardiography*, 2007).

grading the severity of stenosis, combining all Doppler and 2D data, and not relying on one specific measurement. Loading conditions influence velocity and pressure gradients; therefore, these parameters vary depending on intercurrent illness of patients with low vs. high cardiac output. In addition, irregular rhythms or tachycardia can make assessment of stenosis severity problematic. Finally, echocardiographic measurements of valve stenosis must be interpreted in the clinical context of the individual patient. The same Doppler echocardiographic measures of stenosis severity may be clinically important for one patient but less significant for another.

II. AORTIC STENOSIS

Echocardiography has become the standard means for evaluation of aortic stenosis (AS) severity. Cardiac catheterization is no longer recommended¹⁻³ except in rare cases when echocardiography is non-diagnostic or discrepant with clinical data.

This guideline details recommendations for recording and measurement of AS severity using echocardiography. However, although accurate quantitation of disease severity is an essential step in patient management, clinical decision-making depends on several other factors, most importantly symptom status. This echocardiographic standards document does not make recommendations for clinical management: these are detailed in the current guidelines for management of adults with valvular heart disease.

A. Causes and Anatomic Presentation

The most common causes of valvular AS are a bicuspid aortic valve with superimposed calcific changes, calcific stenosis of a trileaflet valve, and rheumatic valve disease (Figure 1). In Europe and the USA, bicuspid aortic valve disease accounts for ~50% of all valve replacements for AS.⁴ Calcification of a trileaflet valve accounts for most of the remainder, with a few cases of rheumatic AS. However, worldwide, rheumatic AS is more prevalent.

Anatomic evaluation of the aortic valve is based on a combination of short- and long-axis images to identify the number of leaflets, and to describe leaflet mobility, thickness, and calcification. In addition, the combination of imaging and Doppler allows the determination of the level of obstruction; subvalvular, valvular, or supra-annular. Trans-thoracic imaging usually is adequate, although transesophageal echocardiography (TEE) may be helpful when image quality is suboptimal.

A bicuspid valve most often results from fusion of the right and left coronary cusps, resulting in a larger anterior and smaller posterior cusp with both coronary arteries arising from the anterior cusp (~80% of cases), or fusion of the right and non-coronary cusps resulting in a larger right than left cusp with one coronary artery arising from each cusp (about 20% of cases).^{5,6} Fusion of the left and non-coronary cusps is rare. Diagnosis is most reliable when the two cusps are seen in systole with only two commissures framing an elliptical systolic orifice. Diastolic images may mimic a tricuspid valve when a raphe is present. Long-axis views may show an asymmetric closure line, systolic doming, or diastolic prolapse of the cusps but these findings are less specific than a short-axis systolic image. In children and adolescents, a bicuspid valve may be stenotic without extensive calcification. However, in adults, stenosis of a bicuspid aortic valve typically is due to superimposed calcific changes, which often obscures the number of cusps, making determination of bicuspid vs. tricuspid valve difficult.

Calcification of a tricuspid aortic valve is most prominent when the central part of each cusp and commissural fusion is absent, resulting in a stellate-shaped systolic orifice. With calcification of a bicuspid or tricuspid valve, the severity of valve calcification can be graded semi-quantitatively, as mild (few areas of dense echogenicity with little acoustic shadowing), moderate, or severe (extensive thickening and increased echogenicity with a prominent acoustic shadow). The degree of valve calcification is a predictor of clinical outcome.^{4,7}

Rheumatic AS is characterized by commissural fusion, resulting in a triangular systolic orifice, with thickening and calcification most prominent along the edges of the cusps. Rheumatic disease nearly always affects the mitral valve first, so that rheumatic aortic valve disease is accompanied by rheumatic mitral valve changes. Subvalvular or supra-annular stenosis is distinguished from valvular stenosis based on the site of the increase in velocity seen with colour or pulsed Doppler and on the anatomy of the outflow tract. Subvalvular obstruction may be fixed, due to a discrete membrane or muscular band, with haemodynamics similar to obstruction at the valvular level. Dynamic subaortic obstruction, for example, with hypertrophic cardiomyopathy, refers to obstruction that changes in severity during ventricular ejection, with obstruction developing predominantly in mid-to-late systole, resulting in a late peaking velocity curve. Dynamic obstruction also varies with loading conditions, with increased ob-

Table 1 Recommendations for data recording and measurement for AS quantitation

Data element	Recording	Measurement
LVOT diameter	<ul style="list-style-type: none"> • 2D parasternal long-axis view • Zoom mode • Adjust gain to optimize the blood tissue interface 	<ul style="list-style-type: none"> • Inner edge to inner edge • Mid-systole • Parallel and adjacent to the aortic valve or at the site of velocity measurement (see text) • Diameter is used to calculate a circular CSA
LVOT velocity	<ul style="list-style-type: none"> • Pulsed-wave Doppler • Apical long axis or five-chamber view • Sample volume positioned just on LV side of valve and moved carefully into the LVOT if required to obtain laminar flow curve • Velocity baseline and scale adjusted to maximize size of velocity curve • Time axis (sweep speed) 100 mm/s • Low wall filter setting • Smooth velocity curve with a well-defined peak and a narrow velocity range at peak velocity 	<ul style="list-style-type: none"> • Maximum velocity from peak of dense velocity curve • VTI traced from modal velocity
AS jet velocity	<ul style="list-style-type: none"> • CW Doppler (dedicated transducer) • Multiple acoustic windows (e.g. apical, suprasternal, right parasternal, etc) • Decrease gains, increase wall filter, adjust baseline, and scale to optimize signal • Gray scale spectral display with expanded time scale • Velocity range and baseline adjusted so velocity signal fits but fills the vertical scale 	<ul style="list-style-type: none"> • Maximum velocity at peak of dense velocity curve • Avoid noise and fine linear signals • VTI traced from outer edge of dense signal curve • Mean gradient calculated from traced velocity curve • Report window where maximum velocity obtained
Valve anatomy	<ul style="list-style-type: none"> • Parasternal long- and short-axis views • Zoom mode 	<ul style="list-style-type: none"> • Identify number of cusps in systole, raphe if present • Assess cusp mobility and commissural fusion • Assess valve calcification

struction when ventricular volumes are smaller and when ventricular contractility is increased.

Supravalvular stenosis is uncommon and typically is due to a congenital condition, such as Williams syndrome with persistent or recurrent obstruction in adulthood.

With the advent of percutaneous aortic valve implantation, anatomic assessment appears to become increasingly important for patient selection and planning of the intervention. Besides underlying morphology (bicuspid vs. tricuspid) as well as extent and distribution of calcification, the assessment of annulus dimension is critical for the choice of prosthesis size. For the latter, TEE may be superior to transthoracic echocardiography (TTE). However, standards still have to be defined.

B. How to Assess Aortic Stenosis (Tables 1 and 2)

B.1. Recommendations for Standard Clinical Practice (Level 1 Recommendation 5 appropriate in all patients with AS) The primary haemodynamic parameters recommended for clinical evaluation of AS severity are:

- AS jet velocity
- Mean transaortic gradient
- Valve area by continuity equation.

B.1.1. Jet velocity. The antegrade systolic velocity across the narrowed aortic valve, or aortic jet velocity, is measured using continuous-wave (CW) Doppler (CWD) ultrasound.^{8–10} Accurate data recording mandates multiple acoustic windows in order to determine the highest velocity (apical and suprasternal or right parasternal most frequently yield the highest velocity; rarely subcostal or supraclavicular windows may be required). Careful patient positioning and adjustment of transducer position and angle are crucial as velocity measurement assumes a parallel intercept angle between the ultrasound beam and direction of blood flow, whereas the 3D direction of the aortic jet is unpredictable and usually cannot be visualized. AS jet velocity is defined as the highest velocity signal obtained from any window after a careful examination; lower values from other views are not reported. The acoustic window that provides the highest aortic jet velocity is noted in the report and usually remains constant on sequential studies in an individual patient.

Occasionally, colour Doppler is helpful to avoid recording the CWD signal of an eccentric mitral regurgitation (MR) jet, but is usually not helpful for AS jet direction. Any deviation from a parallel intercept angle results in velocity underestimation; however, the degree of underestimation is 5% or less if the intercept angle is within 15° of parallel. ‘Angle correction’ should not be used because it is likely to introduce more error given the unpredictable jet direction. A

Table 2 Measures of AS severity obtained by Doppler echocardiography

	Units	Formula / Method	Cutoff for Severe	Concept	Advantages	Limitations
AS jet velocity 6-10, 12	m/s	Direct measurement	4.0	Velocity increases as stenosis severity increase.	Direct measurement of velocity. Strongest predictor of clinical outcome.	Correct measurement requires parallel alignment of ultrasound beam. Flow dependent.
Mean gradient 6-10	mm Hg	$\Delta P = \sum 4v^2 / N$	40 or 50	Pressure gradient calculated from velocity using the Bernoulli equation	Mean gradient is averaged from the velocity curve. Units comparable to invasive measurements.	Accurate pressure gradients depend on accurate velocity data. Flow dependent.
Continuity equation valve area 16, 17, 23	cm ²	$AVA = (CSA_{LVOT} \times VT_{LVOT}) / VT_{AV}$	1.0	Volume flow proximal to and in the stenotic orifice is equal.	Measures effective orifice area. Feasible in nearly all patients. Relatively flow independent.	Requires LVOT diameter and flow velocity data, along with aortic velocity. Measurement error more likely.
Simplified continuity equation 18, 21	cm ²	$AVA = (CSA_{LVOT} \times V_{LVOT}) / V_{AV}$	1.0	The ratio of LVOT to aortic velocity is similar to the ratio of VTIs with native aortic valve stenosis.	Uses more easily measured velocities instead of VTIs.	Less accurate if shape of velocity curves is atypical.
Velocity Ratio 19, 18	none	$VR = \frac{V_{LVOT}}{V_{AV}}$	0.25	Effective aortic valve area expressed as a proportion of the LVOT area.	Doppler-only method. No need to measure LVOT size, less variability than continuity equation.	Limited longitudinal data. Ignores LVOT size variability beyond patient size dependence.
Planimetry of Aortic Valve Area 26, 34	cm ²	TTE, TEE, 3D-echo	1.0	Anatomic (geometric) cross-sectional area of the aortic valve orifice as measured by 2D or 3D echo.	Useful if Doppler measurements are unavailable.	Contraction coefficient (anatomic / effective valve area) may be variable. Difficult with severe valve calcification.
LV % Stroke Work Loss 27	%	$\%SWL = \frac{\Delta P}{\Delta P + SBP} \times 100$	25	Work of the LV wasted each systole for flow to cross the aortic valve, expressed as a % of total systolic work.	Very easy to measure. Related to outcome in one longitudinal study.	Flow-dependent. Limited longitudinal data.
Recovered Pressure Gradient 33, 32	mm Hg	$P_{rec} - P_{vc} = 4 \cdot v^2 \cdot 2 \cdot \frac{AVA}{AA} \left(1 - \frac{AVA}{AA} \right)$	-	Pressure difference between the LV and the aorta, slightly distal to the vena contracta, where distal pressure has increased.	Closer to the global hemodynamic burden caused by AS in terms of adaptation of the cardiovascular system. Relevant at high flow states and in patients with small ascending aorta.	Introduces complexity and variability related to the measurement of the ascending aorta. No prospective studies showing real advantages over established methods.
Energy Loss Index 35	cm ² /m ²	$ELI = \frac{AVA}{AA} \cdot \frac{AA}{AA - AVA} \cdot \frac{1}{BSA}$	0.5	Equivalent to the concept of AVA, but correcting for distal recovered pressure in the ascending aorta.	(As above) Most exact measurement of AS in terms of flow-dynamics. Increased prognostic value in one longitudinal study.	Introduces complexity and variability related to the measurement of the ascending aorta.
Valvulo-Arterial Impedance ³¹	mm Hg/ml/m ²	$Z_{va} = \frac{\Delta P_{vc} + SBP}{SVI}$	5	Global systolic load imposed to the LV, where the numerator represents an accurate estimation of total LV pressure.	Integrates information on arterial load to the hemodynamic burden of AS, and systemic hypertension is a frequent finding in calcific-degenerative disease.	Although named "impedance", only the steady-flow component (i.e. mean resistance) is considered. No longitudinal prospective study available.
Aortic Valve Resistance 28, 29	dynes/s/cm ⁵	$AVR = \frac{\Delta P}{Q} = \frac{4 \cdot v^2}{\pi \cdot (r_{vc}^2 - r_{rest}^2)} \cdot 1333$	280	Resistance to flow caused by AS, assuming the hydrodynamics of a tubular (non flat) stenosis.	Initially suggested to be less flow-dependent in low-flow AS, but subsequently shown to not be true.	Flow dependence. Limited prognostic value. Unrealistic mathematic modeling of flow-dynamics of AS.
Projected Valve Area at Normal Flow Rate 30	cm ²	$AVA_{proj} = AVA_{rest} + VC \cdot (250 - Q_{rest})$	1.0	Estimation of AVA at normal flow rate by plotting AVA vs. flow and calculating the slope of regression (DSE).	Accounts for the variable changes in flow during DSE in low flow low gradient AS, provides improved interpretation of AVA changes.	Clinical impact still to be shown. Outcome of low-flow AS appears closer related to the presence / absence of LV contractility reserve.

Recommendation for clinical application: (1) appropriate in all patients with AS (yellow); (2) reasonable when additional information is needed in selected patients (green); and (3) not recommended for clinical use (blue).

VR, Velocity ratio; TVI, time-velocity integral; LVOT, LV outflow tract; AS, AS jet; TTE and TEE, transthoracic and transesophageal echocardiography; SWL, stroke work loss; ΔP , mean transvalvular systolic pressure gradient; SBP, systolic blood pressure; P_{distal} , pressure at the ascending aorta; P_{vc} , pressure at the vena contracta; AVA, continuity-equation-derived aortic valve area; v, velocity of AS jet; AA, size of the ascending aorta; ELI, energy-loss coefficient; BSA, body-surface area; AVR, aortic valve resistance; Q, mean systolic transvalvular flow-rate; AVA_{proj} , projected aortic valve area; AVA_{rest} , AVA at rest; VC, valve compliance derived as the slope of regression line fitted to the AVA versus Q plot; Q_{rest} , flow at rest; DSE, dobutamine stress echocardiography; N, number of instantaneous measurements.

dedicated small dual-crystal CW transducer is recommended both due to a higher signal-to-noise ratio and to allow optimal transducer positioning and angulation, particularly when suprasternal and right parasternal windows are used. However, when stenosis is only mild (velocity <3 m/s) and leaflet opening is well seen, a combined imaging-Doppler transducer may be adequate.

The spectral Doppler signal is recorded with the velocity scale adjusted so the signal fills, but fits, on the vertical axis, and with a time scale on the x-axis of 100 mm/s. Wall (or high pass) filters are set at a high level and gain is decreased to optimize identification of the velocity curve.

Grey scale is used because this scale maps signal strength using a decibel scale that allows visual separation of noise and transit time effect from the velocity signal. In addition, all the validation and interobserver variability studies were done using this mode. Colour scales have variable approaches to matching signal strength to colour hue or intensity and are not recommended unless a decibel scale can be verified.

A smooth velocity curve with a dense outer edge and clear maximum velocity should be recorded. The maximum velocity is measured at the outer edge of the dark signal; fine linear signals at the peak of the curve are due to the transit time effect and should not be

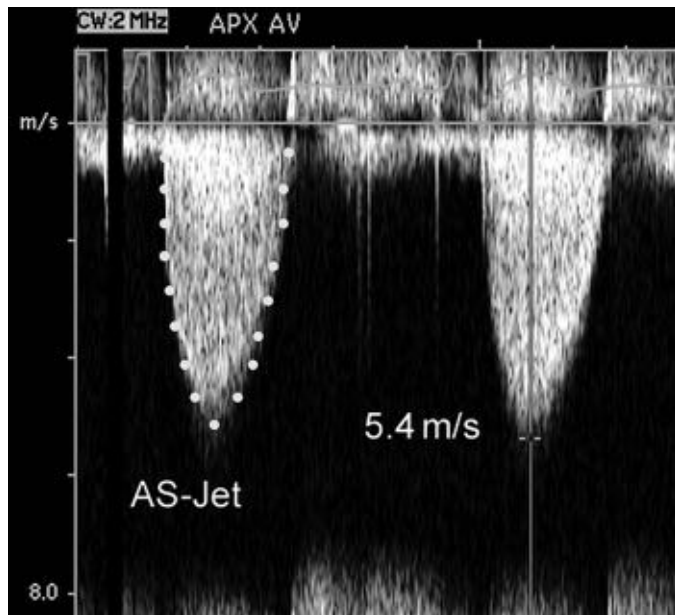


Figure 2 Continuous-wave Doppler of severe aortic stenosis jet showing measurement of maximum velocity and tracing of the velocity curve to calculate mean pressure gradient.

included in measurements. Some colour scales ‘blur’ the peak velocities, sometimes resulting in overestimation of stenosis severity. The outer edge of the dark ‘envelope’ of the velocity curve (Figure 2) is traced to provide both the velocity–time integral (VTI) for the continuity equation and the mean gradient (see below).

Usually, three or more beats are averaged in sinus rhythm, averaging of more beats is mandatory with irregular rhythms (at least 5 consecutive beats). Special care must be taken to select representative sequences of beats and to avoid post-extrasystolic beats.

The shape of the CW Doppler velocity curve is helpful in distinguishing the level and severity of obstruction. Although the time course of the velocity curve is similar for fixed obstruction at any level (valvular, subvalvular, or supra-ventricular), the maximum velocity occurs later in systole and the curve is more rounded in shape with more severe obstruction. With mild obstruction, the peak is in early systole with a triangular shape of the velocity curve, compared with the rounded curve with the peak moving towards midsystole in severe stenosis, reflecting a high gradient throughout systole. The shape of the CWD velocity curve also can be helpful in determining whether the obstruction is fixed or dynamic. Dynamic subaortic obstruction shows a characteristic late-peaking velocity curve, often with a concave upward curve in early systole (Figure 3).

B.1.2. Mean transaortic pressure gradient. The difference in pressure between the left ventricular (LV) and aorta in systole, or transvalvular aortic gradient, is another standard measure of stenosis severity.^{8–10} Gradients are calculated from velocity information, and peak gradient obtained from the peak velocity does therefore not add additional information as compared with peak velocity. However, the calculation of the mean gradient, the average gradient across the valve occurring during the entire systole, has potential advantages and should be reported. Although there is overall good correlation between peak gradient and mean gradient, the relationship between peak and mean gradient depends on the shape of the velocity curve,

which varies with stenosis severity and flow rate. The mean transaortic gradient is easily measured with current echocardiography systems and provides useful information for clinical decision-making.

Transaortic pressure gradient (ΔP) is calculated from velocity (v) using the Bernoulli equation as:

$$\Delta P = 4v^2$$

The maximum gradient is calculated from maximum velocity:

$$\Delta P_{\max} = 4v_{\max}^2$$

and the mean gradient is calculated by averaging the instantaneous gradients over the ejection period, a function included in most clinical instrument measurement packages using the traced velocity curve. Note that the mean gradient requires averaging of instantaneous mean gradients and cannot be calculated from the mean velocity.

This clinical equation has been derived from the more complex Bernoulli equation by assuming that viscous losses and acceleration effects are negligible and by using an approximation for the constant that relates to the mass density of blood, a conversion factor for measurement units.

In addition, the simplified Bernoulli equation assumes that the proximal velocity can be ignored, a reasonable assumption when velocity is <1 m/s because squaring a number <1 makes it even smaller. When the proximal velocity is over 1.5 m/s or the aortic velocity is <3.0 m/s, the proximal velocity should be included in the Bernoulli equation so that

$$\Delta P = 4(v_{\max}^2 - v_{\text{proximal}}^2)$$

when calculating maximum gradients. It is more problematic to include proximal velocity in mean gradient calculations as each point on the ejection curve for the proximal and jet velocities would need to be matched and this approach is not used clinically. In this situation, maximum velocity and gradient should be used to grade stenosis severity.

Sources of error for pressure gradient calculations

In addition to the above-mentioned sources of error (malalignment of jet and ultrasound beam, recording of MR jet, neglect of an elevated proximal velocity), there are several other limitations of transaortic pressure gradient calculations. Most importantly, any underestimation of aortic velocity results in an even greater underestimation in gradients, due to the squared relationship between velocity and pressure difference. There are two additional concerns when comparing pressure gradients calculated from Doppler velocities to pressures measured at cardiac catheterization. First, the peak gradient calculated from the maximum Doppler velocity represents the maximum instantaneous pressure difference across the valve, not the difference between the peak LV and peak aortic pressure measured from the pressure tracings. Note that peak LV and peak aortic pressure do not occur at the same point in time; so, this difference does not represent a physiological measurement and this peak-to-peak difference is less than the maximum instantaneous pressure difference. The second concern is the phenomenon of pressure recovery (PR). The conversion of potential energy to kinetic energy across a narrowed valve results in a high velocity and a drop in pressure. However, distal to the orifice, flow decelerates again. Although some of the kinetic energy dissipates into heat due to turbulences and viscous losses, some of the kinetic energy will be reconverted into potential energy with a corresponding increase in pressure, the so-called PR. Pressure recovery is greatest in stenoses with gradual distal widening since occurrence of turbulences is then

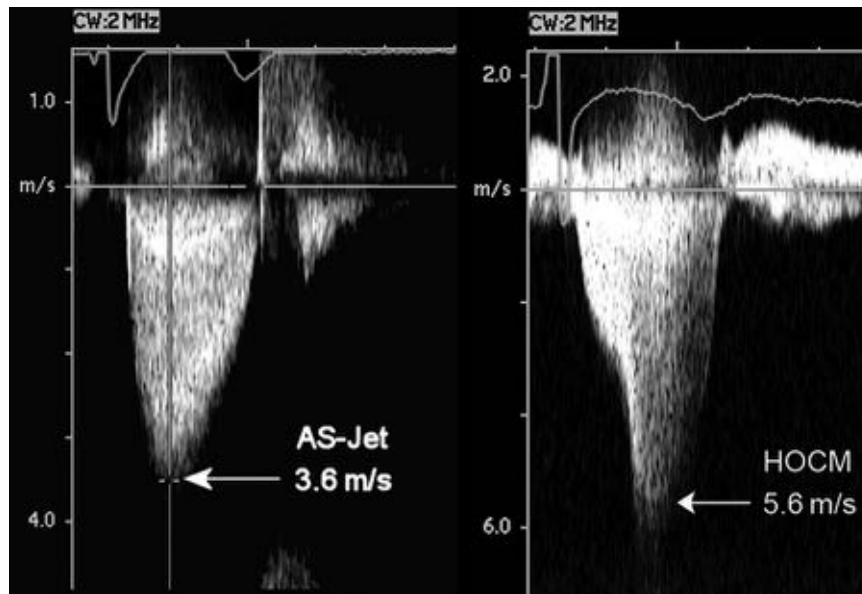


Figure 3 An example of moderate aortic stenosis (left) and dynamic outflow obstruction in hypertrophic cardiomyopathy (right). Note the different shapes of the velocity curves and the later maximum velocity with dynamic obstruction.

reduced. Aortic stenosis with its abrupt widening from the small orifice to the larger aorta has an unfavourable geometry for pressure recovery. In AS, PR (in mmHg) can indeed be calculated from the Doppler gradient that corresponds to the initial pressure drop across the valve (i.e. $4v^2$), the effective orifice area as given by the continuity equation (EOA) and the cross-sectional area (CSA) of the ascending aorta (AoA) by the following equation: $PR = 4v^2 \times 2EOA/AoA \times (1 - EOA/AoA)$.¹¹ Thus, PR is basically related to the ratio of EOA/AoA. As a relatively small EOA is required to create a relevant gradient, AoA must also be relatively small to end up with a ratio favouring PR. For clinical purposes, aortic sizes, therefore, appear to be the key player and PR must be taken into account primarily in patients with a diameter of the ascending aorta <30 mm.¹¹ It may be clinically relevant particularly in congenital AS. However, in most adults with native AS, the magnitude of PR is small and can be ignored as long as the diameter of the aorta is >30 mm. When the aorta is <30 mm, however, one should be aware that the initial pressure drop from LV to the vena contracta as reflected by Doppler measurement may be significantly higher than the actual net pressure drop across the stenosis, which represents the pathophysiologically relevant measurement.¹¹

Current guidelines for decision-making in patients with valvular heart disease recommend non-invasive evaluation with Doppler echocardiography.^{1,2,12,13} Cardiac catheterization is not recommended except in cases where echocardiography is non-diagnostic or is discrepant with clinical data. The prediction of clinical outcomes has been primarily studied using Doppler velocity data.

B.1.3. Valve area. Doppler velocity and pressure gradients are flow dependent; for a given orifice area, velocity and gradient increase with an increase in transaortic flow rate, and decrease with a decrease in flow rate. Calculation of the stenotic orifice area or aortic valve area (AVA) is helpful when flow rates are very low or very high, although even the degree of valve opening varies to some degree with flow rate (see below).

Aortic valve area is calculated based on the continuity-equation (Figure 4) concept that the stroke volume (SV) ejected through the

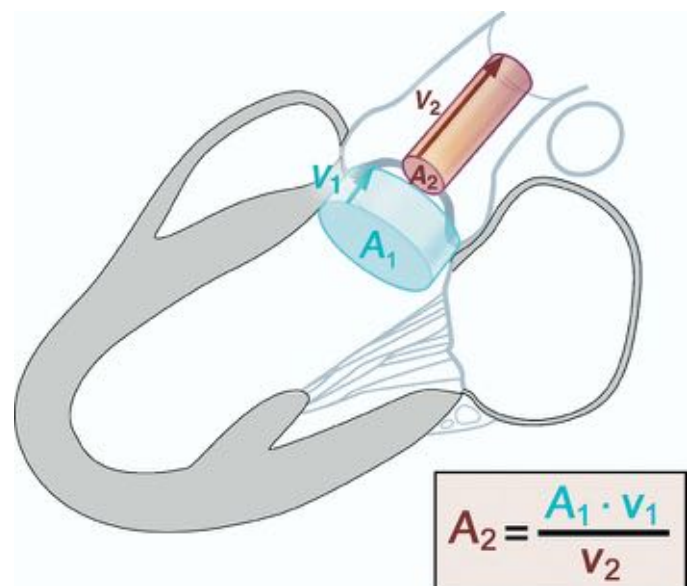


Figure 4 Schematic diagram of continuity equation.

LV outflow tract (LVOT) all passes through the stenotic orifice (AVA) and thus SV is equal at both sites:

$$SV_{AV} = SV_{LVOT}$$

Because volume flow rate through any CSA is equal to the CSA times flow velocity over the ejection period (the VTI of the systolic velocity curve), this equation can be rewritten as:

$$AVA \times VTI_{AV} = CSA_{LVOT} \times VTI_{LVOT}$$

Solving for AVA yields the continuity equation^{14,15}

$$AVA = \frac{CSA_{LVOT} \times VTI_{LVOT}}{VTI_{AV}}$$

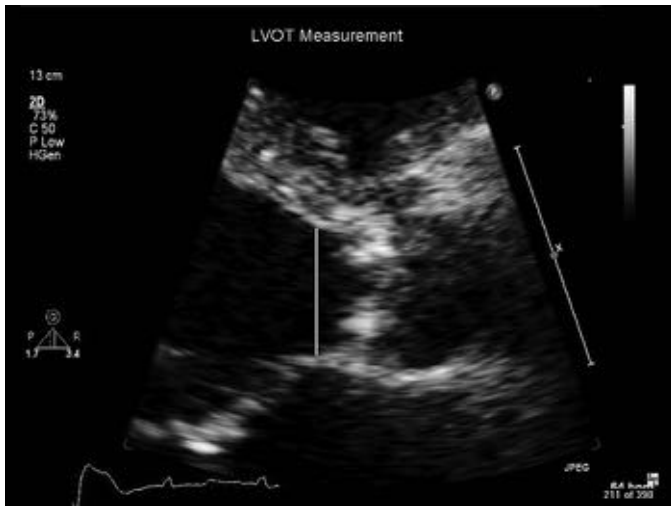


Figure 5 Left ventricular outflow tract diameter is measured in the parasternal long-axis view in mid-systole from the white-black interface of the septal endocardium to the anterior mitral leaflet, parallel to the aortic valve plane and within 0.5–1.0 cm of the valve orifice.

Calculation of continuity-equation valve area requires three measurements:

- AS jet velocity by CWD
- LVOT diameter for calculation of a circular CSA
- LVOT velocity recorded with pulsed Doppler.

AS jet velocity is recorded with CWD and the VTI is measured as described above.

Left ventricular outflow tract stroke volume

Accurate SV calculations depend on precisely recording the LVOT diameter and velocity. It is essential that both measurements are made at the same distance from the aortic valve. When a smooth velocity curve can be obtained at the annulus, this site is preferred (i.e. particularly in congenital AS with doming valve). However, flow acceleration at the annulus level and even more proximally occurs in many patients, particularly those with calcific AS, so that the sample volume needs to be moved apically from 0.5 to 1.0 cm to obtain a laminar flow curve without spectral dispersion. In this case, the diameter measurement should be made at this distance from the valve (Figure 5). However, it should be remembered that LVOT becomes progressively more elliptical (rather than circular) in many patients, which may result in underestimation of LVOT CSA and in consequence underestimation of SV and eventually AVA.¹⁶ Diameter is measured from the inner edge to inner edge of the septal endocardium, and the anterior mitral leaflet in mid-systole. Diameter measurements are most accurate using the zoom mode with careful angulation of the transducer and with gain and processing adjusted to optimize the images. Usually three or more beats are averaged in sinus rhythm, averaging of more beats is appropriate with irregular rhythms (at least 5 consecutive beats). With careful attention to the technical details, diameter can be measured in nearly all patients. Then, the CSA of the LVOT is calculated as the area of a circle with the limitations mentioned above:

$$CSA_{LVOT} = \pi \left(\frac{D}{2} \right)^2$$

where *D* is diameter. LVOT velocity is recorded with pulsed Doppler

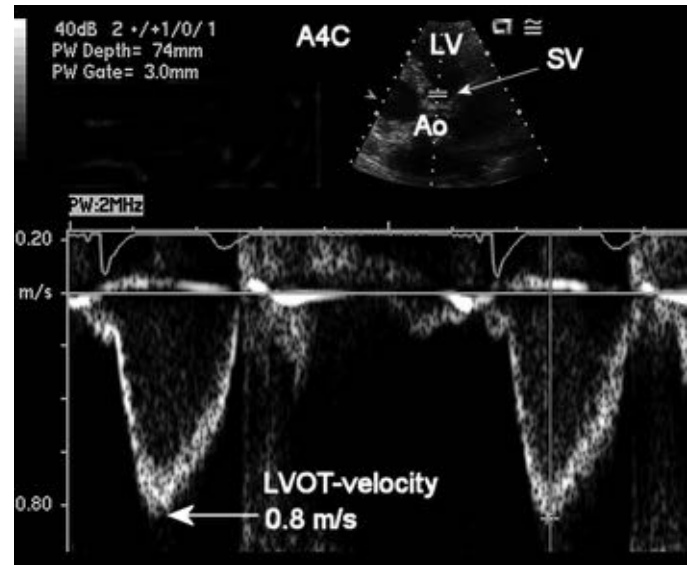


Figure 6 Left ventricular outflow tract (LVOT) velocity is measured from the apical approach either in an apical long-axis view or an anteriorly angulated four-chamber view (as shown here). Using pulsed-Doppler, the sample volume (SV), with a length (or gate) of 3–5 mm, is positioned on the LV side of the aortic valve, just proximal to the region of flow acceleration into the jet. An optimal signal shows a smooth velocity curve with a narrow velocity range at each time point. Maximum velocity is measured as shown. The VTI is measured by tracing the modal velocity (middle of the dense signal) for use in the continuity equation or calculation of stroke volume.

from an apical approach, in either the anteriorly angulated four-chamber view (or 'five-chamber view') or in the apical long-axis view. The pulsed-Doppler sample volume is positioned just proximal to the aortic valve so that the location of the velocity recording matches the LVOT diameter measurement. When the sample volume is optimally positioned, the recording (Figure 6) shows a smooth velocity curve with a well-defined peak, narrow band of velocities throughout systole. As mentioned above, this may not be the case in many patients at the annulus due to flow convergence resulting in spectral dispersion. In this case, the sample volume is then slowly moved towards the apex until a smooth velocity curve is obtained. The VTI is measured by tracing the dense modal velocity throughout systole.¹⁷

Limitations of continuity-equation valve area

The clinical measurement variability for continuity-equation valve area depends on the variability in each of the three measurements, including both the variability in acquiring the data and variability in measuring the recorded data. AS jet and LVOT velocity measurements have a very low intra- and interobserver variability (~3–4%) both for data recording and measurement in an experienced laboratory. However, the measurement variability for LVOT diameter ranges from 5% to 8%. When LVOT diameter is squared for calculation of CSA, it becomes the greatest potential source of error in the continuity equation. When transthoracic images are not adequate for the measurement of LVOT diameter, TEE measurement is recommended if this information is needed for clinical decision-making.

Accuracy of SV measurements in the outflow tract also assumes laminar flow with a spatially flat profile of flow (e.g. velocity is the same in the centre and at the edge of the flow stream). When subaortic flow velocities are abnormal, for example, with dynamic

subaortic obstruction or a subaortic membrane, SV calculations at this site are not accurate. With combined stenosis and regurgitation, high subaortic flow rates may result in a skewed flow profile across the outflow tract that may limit the accuracy. When LVOT velocity must be measured with some distance to annulus due to flow convergence, the velocity profile may no longer be flat but rather skewed with highest velocities present at the septum. Placement of the sample volume in the middle of the LVOT cross-section may nevertheless give a measurement reasonably close to the average. Placement closer to the septum or the mitral anterior leaflet may, however, yield higher or lower measurements, respectively.

Continuity-equation valve area calculations have been well validated in both clinical and experimental studies.^{14,15,18} In addition, continuity-equation valve areas are a reliable parameter for prediction of clinical outcome and for clinical decision-making.^{12,19} Of course, valve area calculations are dependable only when there is careful attention to technical aspects of data acquisition and measurement as detailed above. In addition, there are some theoretical concerns about continuity-equation valve areas.

First, the continuity-equation measures the effective valve area—the area of the flow stream as it passes through the valve—not the anatomic valve area. The effective valve area is smaller than the anatomic valve area due to contraction of the flow stream in the orifice, as determined by the contraction and discharge coefficients for a given orifice geometry.²⁰ Although, the difference between effective and anatomic valve area may account for some of the discrepancies between Doppler continuity equation and catheterization Gorlin equation valve areas, there now are ample clinical-outcome data validating the use of the continuity equation. The weight of the evidence now supports the concept that effective, not anatomic, orifice area is the primary predictor of clinical outcome.

The second potential limitation of valve area as a measure of stenosis severity is the observed changes in valve area with changes in flow rate.^{21,22} In adults with AS and normal LV function, the effects of flow rate are minimal and resting effective valve area calculations are accurate. However, this effect may be significant when concurrent LV dysfunction results in decreased cusp opening and a small effective orifice area even though severe stenosis is not present. The most extreme example of this phenomenon is the lack of aortic valve opening when a ventricular assist device is present. Another example is the decreased opening of normal cusps seen frequently with severe LV systolic dysfunction. However, the effect of flow rate on valve area can be used to diagnostic advantage in AS with LV dysfunction to identify those with severe AS, as discussed below.

Serial measurements

When serial measurements are performed during follow-up, any significant changes in results should be checked in detail:

- make sure that aortic jet velocity is recorded from the same window with the same quality (always report the window where highest velocities can be recorded).
- when AVA changes, look for changes in the different components incorporated in the equation. LVOT size rarely changes over time in adults.

B.2. Alternate measures of stenosis severity (Level 2 Recommendation 5 reasonable when additional information is needed in selected patients) *B.2.1. Simplified continuity equation.* The simplified continuity equation is based on the concept that in native aortic valve stenosis the shape of the velocity curve in the outflow tract and aorta is similar so that the ratio of LVOT to aortic jet

VTI is nearly identical to the ratio of the LVOT to aortic jet maximum velocity (V).^{18,23} Thus, the continuity equation can be simplified to:

$$AVA = \frac{CSA_{LVOT} \times V_{LVOT}}{V_{AV}}$$

This method is less well accepted because some experts are concerned that results are more variable than using VTIs in the equation.

B.2.2. Velocity ratio. Another approach to reducing error related to LVOT diameter measurements is removing CSA from the simplified continuity equation. This dimensionless velocity ratio expresses the size of the valvular effective area as a proportion of the CSA of the LVOT.

$$\text{Velocity ratio} = \frac{V_{LVOT}}{V_{AV}}$$

Substitution of the time-velocity integral can also be used as there was a high correlation between the ratio using time-velocity integral and the ratio using peak velocities. In the absence of valve stenosis, the velocity ratio approaches 1, with smaller numbers indicating more severe stenosis. Severe stenosis is present when the velocity ratio is 0.25 or less, corresponding to a valve area 25% of normal.¹⁸ To some extent, the velocity ratio is normalized for body size because it reflects the ratio of the actual valve area to the expected valve area in each patient, regardless of body size. However, this measurement ignores the variability in LVOT size beyond variation in body size.

B.2.3. Aortic valve area planimetry. Multiple studies have evaluated the method of measuring anatomic (geometric) AVA by direct visualization of the valvular orifice, either by 2D or 3D TTE or TEE.^{24–26} Planimetry may be an acceptable alternative when Doppler estimation of flow velocities is unreliable. However, planimetry may be inaccurate when valve calcification causes shadows or reverberations limiting identification of the orifice. Caution is also needed to ensure that the minimal orifice area is identified rather than a larger apparent area proximal to the cusp tips, particularly in congenital AS with a doming valve. In addition, as stated previously, effective, rather than anatomic, orifice area is the primary predictor of outcome.

B.3. Experimental descriptors of stenosis severity (Level 3 Recommendation = not recommended for routine clinical use)

Other haemodynamic measurements of severity such as valve resistance, LV percentage stroke-work loss, and the energy-loss coefficient are based on different mathematical derivations of the relationship between flow and the trans-valvular pressure drop.^{27–31} Accounting for PR in the ascending aorta has demonstrated to improve the agreement between invasively and non-invasively derived measurements of the transvalvular pressure gradient, and is particularly useful in the presence of a high output state, a moderately narrowed valve orifice and, most importantly, a non-dilated ascending aorta.^{11,32}

A common limitation of most these new indices is that long-term longitudinal data from prospective studies are lacking. Consequently, a robust validation of clinical-outcome efficacy of all these indices is pending, and they are seldom used for clinical decision-making.²⁷

B.4. Effects of concurrent conditions on assessment of severity *B.4.1. Concurrent left ventricular systolic dysfunction.*

When LV systolic dysfunction co-exists with severe AS, the AS velocity and gradient may be low, despite a small valve area; a condition termed 'low-flow low-gradient AS'. A widely used definition of low-flow low-gradient AS includes the following conditions:

- Effective orifice area $<1.0 \text{ cm}^2$;^{1,33,34}
- LV ejection fraction $<40\%$; and
- Mean pressure gradient $<30\text{--}40 \text{ mmHg}$

Dobutamine stress provides information on the changes in aortic velocity, mean gradient, and valve area as flow rate increases, and also provides a measure of the contractile response to dobutamine, measured by the change in SV or ejection fraction. These data may be helpful to differentiate two clinical situations:

- Severe AS causing LV systolic dysfunction. The transaortic velocity is flow dependent; so, LV failure can lead to a patient with severe AS having an apparently moderate transaortic peak velocity and mean pressure gradient associated with a small effective orifice area. In this situation, aortic valve replacement will relieve afterload and may allow the LV ejection fraction to increase towards normal.
- Moderate AS with another cause of LV dysfunction (e.g. myocardial infarct or a primary cardiomyopathy). The effective orifice area is then low because the LV does not generate sufficient energy to overcome the inertia required to open the aortic valve to its maximum possible extent. In this situation, aortic valve replacement may not lead to a significant improvement in LV systolic function.

A patient with a low ejection fraction but a resting AS velocity 4.0 m/s or mean gradient 40 mmHg does not have a poor left ventricle (LV). The ventricle is demonstrating a normal response to high afterload (severe AS), and ventricular function will improve after relief of stenosis. This patient does not need a stress echocardiogram.

The protocol for dobutamine stress echocardiography for evaluation of AS severity in setting of LV dysfunction uses a low dose starting at 2.5 or 5 mg/kg/min with an incremental increase in the infusion every $3\text{--}5 \text{ min}$ to a maximum dose of $10\text{--}20 \text{ mg/kg/min}$. There is a risk of arrhythmia so there must be medical supervision and high doses of dobutamine should be avoided. The infusion should be stopped as soon as a positive result is obtained or when the heart rate begins to rise more than $10\text{--}20 \text{ bpm}$ over baseline or exceeds 100 bpm , on the assumption that the maximum inotropic effect has been reached. In addition, dobutamine administration should also be terminated when symptoms, blood pressure fall, or significant arrhythmias occur.

Doppler data are recorded at each stage including LVOT velocity recorded from the apical approach. AS jet velocity optimally is recorded from the window that yields the highest velocity signal but some laboratories prefer to use comparative changes from an apical window to facilitate rapid data acquisition. The LVOT diameter is measured at baseline and the same diameter is used to calculate the continuity-equation valve area at each stage. Measurement of biplane ejection fraction at each stage is helpful to assess the improvement in LV contractile function.

The report of the dobutamine stress echocardiographic study should include AS velocity, mean gradient, valve area, and ejection fraction preferably at each stage (to judge reliability of measurements) but at least at baseline and peak dose. The role of dobutamine stress echocardiography in decision-making in adults with AS is controversial and beyond the scope of this document. The findings we recommend as reliable are:

- An increase in valve area to a final valve area $>1.0 \text{ cm}^2$ suggests that stenosis is not severe.³⁵

- Severe stenosis is suggested by an AS jet >4.0 or a mean gradient $>40 \text{ mmHg}$ provided that valve area does not exceed 1.0 cm^2 at any flow rate.³⁴
- Absence of contractile reserve (failure to increase SV or ejection fraction by $>20\%$) is a predictor of a high surgical mortality and poor long-term outcome although valve replacement may improve LV function and outcome even in this subgroup.³⁶

For all other findings, more scientific data are required before they can be included in recommendations for clinical decision-making.

B.4.2. Exercise stress echocardiography. As described in the previous section, dobutamine stress echocardiography is applied to assess contractile reserve and AS severity in the setting of LV dysfunction. In addition, exercise stress echocardiography has been used to assess functional status and AS severity. Several investigators have suggested that the changes in haemodynamics during exercise study might provide a better index of stenosis severity than a single resting value. Specifically, impending symptom onset can be identified by a fixed valve area that fails to increase with an increase in transaortic volume flow rate. While clinical studies comparing groups of patients support this hypothesis and provide insight into the pathophysiology of the disease process, exercise stress testing to evaluate changes in valve area is not helpful in clinical decision-making in individual patients and therefore is currently not recommended for assessment of AS severity in clinical practice. While exercise testing has become accepted for risk stratification and assessment of functional class in asymptomatic severe AS,^{1,2} it remains uncertain whether the addition of echocardiographic data is of incremental value in this setting. Although the increase in mean pressure gradient with exercise has been reported to predict outcome and provide information beyond a regular exercise test,²² more data are required to validate this finding and recommend its use in clinical practice.

B.4.3. Left ventricular hypertrophy. Left ventricular hypertrophy commonly accompanies AS either as a consequence of valve obstruction or due to chronic hypertension. Ventricular hypertrophy typically results in a small ventricular cavity with thick walls and diastolic dysfunction, particularly in elderly women with AS. The small LV ejects a small SV so that, even when severe stenosis is present, the AS velocity and mean gradient may be lower than expected for a given valve area. Continuity-equation valve area is accurate in this situation. Many women with small LV size also have a small body size (and LVOT diameter), so indexing valve area to body size may be helpful.

B.4.4. Hypertension. Hypertension accompanies AS in $35\text{--}45\%$ of patients. Although a recent in vitro study has demonstrated that systemic pressure may not directly affect gradient and valve area measurements,³⁷ increasing LV pressure load may cause changes in ejection fraction and flow. The presence of hypertension may therefore primarily affect flow and gradients but less AVA measurements. Nevertheless, evaluation of AS severity^{38–40} with uncontrolled hypertension may not accurately reflect disease severity. Thus, control of blood pressure is recommended before echocardiographic evaluation, whenever possible. The echocardiographic report should always include a blood pressure measurement recorded at the time of the examination to allow comparison between serial echocardiographic studies and with other clinical data.

B.4.5. Aortic regurgitation. About 80% of adults with AS also have aortic regurgitation (AR) but regurgitation is usually only mild or moderate in severity and measures of AS severity are not significantly affected. When severe AR accompanies AS, measures of AS severity remain accurate including maximum velocity, mean gradient, and

Table 3 Recommendations for classification of AS severity

	Aortic sclerosis	Mild	Moderate	Severe
Aortic jet velocity (m/s)	≤ 2.5 m/s	2.6–2.9	3.0–4.0	> 4.0
Mean gradient (mmHg)	—	< 20 ($< 30^a$)	20–40 ^b (30–50 ^a)	$> 40^b$ ($> 50^a$)
AVA (cm ²)	—	> 1.5	1.0–1.5	< 1.0
Indexed AVA (cm ² /m ²)	—	> 0.85	0.60–0.85	< 0.6
Velocity ratio	—	> 0.50	0.25–0.50	< 0.25

^aESC Guidelines.^bAHA/ACC Guidelines.

valve area. However, because of the high transaortic volume flow rate, maximum velocity, and mean gradient will be higher than expected for a given valve area. In this situation, reporting accurate quantitative data for the severity of both stenosis and regurgitation⁴¹ is helpful for clinical decision-making. The combination of moderate AS and moderate AR is consistent with severe combined valve disease.

B.4.6. Mitral valve disease. Mitral regurgitation is common in elderly adults with AS either as a consequence of LV pressure overload or due to concurrent mitral valve disease. With MR, it is important to distinguish regurgitation due to a primary abnormality of the mitral valve from secondary regurgitation related to AS. Left ventricular size, hypertrophy, and systolic and diastolic functions should be evaluated using standard approaches, and pulmonary systolic pressure should be estimated from the tricuspid regurgitant jet velocity and estimated right atrial pressure. Mitral regurgitation severity does not affect evaluation of AS severity except for two possible confounders. First, with severe MR, transaortic flow rate may be low resulting in a low gradient even when severe AS is present; valve area calculations remain accurate in this setting. Second, a high-velocity MR jet may be mistaken for the AS jet as both are systolic signals directed away from the apex. Timing of the signal is the most reliable way to distinguish the CWD velocity curve of MR from AS; MR is longer in duration, starting with mitral valve closure and continuing until mitral valve opening. The shape of the MR velocity curve also may be helpful with chronic regurgitation but can appear similar to AS with acute severe MR. High driving pressure (high LV pressure due to AS) may cause MR severity overestimation if jet size is primarily used to evaluate MR. Careful evaluation of MR mechanism is crucial for the decision whether to also operate on the mitral valve. Mitral stenosis (MS) may result in low cardiac output and, therefore, low-flow low-gradient AS.

B.4.7. High cardiac output. High cardiac output in patients on haemodialysis, with anaemia, AV fistula, or other high flow conditions may cause relatively high gradients in the presence of mild or moderate AS. This may lead to misdiagnosis of severe disease particularly when it is difficult to calculate AVA in the presence of dynamic LVOT obstruction. In this situation, the shape of the CWD spectrum with a very early peak may help to quantify the severity correctly.

B.4.8. Ascending aorta. In addition to evaluation of AS aetiology and haemodynamic severity, the echocardiographic evaluation of adults with aortic valve disease should include evaluation of the aorta with measurement of diameters at the sinuses of Valsalva and ascending aorta. Aortic root dilation is associated with bicuspid aortic valve disease, the cause of AS in 50% of adults and aortic size may impact the timing and type of intervention. In some cases, additional imaging with CT or CMR may be needed to fully assess the aorta.

C. How to Grade Aortic Stenosis

Aortic stenosis severity is best described by the specific numerical measures of maximum velocity, mean gradient, and valve area. However, general guidelines have been set forth by the ACC/AHA and ESC for categorizing AS severity as mild, moderate, or severe to provide guidance for clinical decision-making. In most patients, these three Level I recommended parameters, in conjunction with clinical data, evaluation of AR and LV functions, are adequate for clinical decision-making. However, in selected patients, such as those with severe LV dysfunction, additional measurements may be helpful. Comparable values for indexed valve area and the dimensionless velocity ratio have been indicated in Table 3, and the category of aortic sclerosis, as distinct from mild stenosis, has been added. When aortic sclerosis is present, further quantitation is not needed. In evaluation of a patient with valvular heart disease, these cut-off values should be viewed with caution; no single calculated number should be relied on for final judgement. Instead, an integrated approach considering AVA, velocity/gradient together with LVEF, flow status, and clinical presentation is strongly recommended. The ACC/AHA and ESC Guidelines for management of valvular heart disease provide recommendations for classification of severity (Table 3).^{1,2}

A normal AVA in adults is ~ 3.0 – 4.0 cm². Severe stenosis is present when valve area is reduced to $\sim 25\%$ of the normal size so that a value of 1.0 cm² is one reasonable definition of severe AS in adults. The role of indexing for body size is controversial, primarily because the current algorithms for defining body size [such as body-surface area (BSA)] do not necessarily reflect the normal AVA in obese patients, because valve area does not increase with excess body weight. However, indexing valve area for BSA is important in children, adolescents, and small adults as valve area may seem severely narrowed when only moderate stenosis is present. Another approach to indexing for body size is to consider the LVOT to AS velocity ratio, in addition to valve area, in clinical decision-making.

We recommend reporting of both AS maximum velocity and mean gradient. In observational clinical studies, a maximum jet velocity of 4 m/s corresponds to a mean gradient of ~ 40 mmHg and a maximum velocity of 3 m/s corresponds to a mean gradient of ~ 20 mmHg. Although there is overall correlation between peak gradient and mean gradient, the relationship between peak and mean gradients depends on the shape of the velocity curve, which varies with stenosis severity and flow rate.

In clinical practice, many patients have an apparent discrepancy in stenosis severity as defined by maximum velocity (and mean gradient) compared with the calculated valve area.

The first step in patients with either a valve area larger or smaller than expected for a given AS maximum velocity (or mean gradient)

is to verify the accuracy of the echocardiographic data (see above for sources of error).

The next step in evaluation of an apparent discrepancy in measure of AS severity is to evaluate LV ejection fraction and the severity of co-existing AR. If cardiac output is low due to small ventricular chamber or a low ejection fraction, a low AS velocity may be seen with a small valve area. If transaortic flow rate is high due to co-existing AR, valve area may be $> 1.0 \text{ cm}^2$ even though AS velocity and mean gradient are high. It may be useful to compare the SV calculated from the LVOT diameter and velocity with the SV measured on 2D echocardiography by the biplane apical method, to confirm a low or high transaortic volume flow rate.

When review of primary data confirms accuracy of measurements and there is no clinical evidence for a reversible high output state (e.g. sepsis, hyperthyroidism), the patient with an AS velocity of $> 4 \text{ m/s}$ and a valve area of $\geq 1.0 \text{ cm}^2$ most likely has combined moderate AS/AR or a large body size. The AS velocity is a better predictor of clinical outcome than valve area in this situation and should be used to define valve disease as 'severe'.

When review of primary data confirms accuracy of measurements and there is no clinical evidence for a low cardiac output state, the patient with an aortic velocity of $< 4.0 \text{ m/s}$ and a valve area of $< 1.0 \text{ cm}^2$ most likely has only moderate AS with a small body size. The velocity of AS is a better measure of stenosis severity when body size is small and transvalvular flow rate is normal (Table 4).

III. MITRAL STENOSIS

Echocardiography plays a major role in decision-making for MS, allowing for confirmation of diagnosis, quantitation of stenosis severity and its consequences, and analysis of valve anatomy.

A. Causes and Anatomic Presentation

Mitral stenosis is the most frequent valvular complication of rheumatic fever. Even in industrialized countries, most cases remain of rheumatic origin as other causes are rare. Given the decrease in the prevalence of rheumatic heart diseases, MS has become the least frequent single left-sided valve disease. However, it still accounts for $\sim 10\%$ of left-sided valve diseases in Europe and it remains frequent in developing countries.^{42, 43}

The main mechanism of rheumatic MS is commissural fusion. Other anatomic lesions are chordal shortening and fusion, and leaflet thickening, and later in the disease course, superimposed calcification, which may contribute to the restriction of leaflet motion.

This differs markedly from degenerative MS, in which the main lesion is annular calcification. It is frequently observed in the elderly and associated with hypertension, atherosclerotic disease, and sometimes AS. However, calcification of the mitral annulus has few or no haemodynamic consequences when isolated and causes more often MR than MS. In rare cases, degenerative MS has haemodynamic consequences when leaflet thickening and/or calcification are associated. This is required to cause restriction of leaflet motion since there is no commissural fusion. Valve thickening or calcification predominates at the base of the leaflets whereas it affects predominantly the tips in rheumatic MS.

Congenital MS is mainly the consequence of abnormalities of the subvalvular apparatus. Other causes are rarely encountered: inflammatory diseases (e.g. systemic lupus), infiltrative diseases, carcinoid heart disease, and drug-induced valve diseases. Leaflet thickening and restriction are common here, while commissures are rarely fused.

Table 4 Resolution of apparent discrepancies in measures of AS severity

<p>AS velocity $> 4 \text{ m/s}$ and AVA $> 1.0 \text{ cm}^2$</p> <ol style="list-style-type: none"> 1. Check LVOT diameter measurement and compare with previous studies^a 2. Check LVOT velocity signal for flow acceleration 3. Calculate indexed AVA when <ol style="list-style-type: none"> a. Height is $< 135 \text{ cm}$ (5'5") b. BSA $< 1.5 \text{ m}^2$ c. BMI < 22 (equivalent to 55 kg or 120 lb at this height). 4. Evaluate AR severity 5. Evaluate for high cardiac output <ol style="list-style-type: none"> a. LVOT stroke volume b. 2D LV EF and stroke volume <p>Likely causes: high output state, moderate-severe AR, large body size</p> <p>AS velocity $\leq 4 \text{ m/s}$ and AVA $\leq 1.0 \text{ cm}^2$</p> <ol style="list-style-type: none"> 1. Check LVOT diameter measurement and compare with previous studies^a 2. Check LVOT velocity signal for distance from valve 3. Calculate indexed AVA when <ol style="list-style-type: none"> a. Height is $< 135 \text{ cm}$ (5'5") b. BSA $< 1.5 \text{ m}^2$ c. BMI < 22 (equivalent to 55 kg or 120 lb at this height) 4. Evaluate for low transaortic flow volume <ol style="list-style-type: none"> a. LVOT stroke volume b. 2D LV EF and stroke volume c. MR severity d. Mitral stenosis 5. When EF $< 55\%$ <ol style="list-style-type: none"> a. Assess degree of valve calcification b. Consider dobutamine stress echocardiography <p>Likely causes: low cardiac output, small body size, severe MR</p>

B. How to Assess Mitral Stenosis

B.1. Indices of Stenosis Severity **B.1.1. Pressure gradient (Level 1 Recommendation).** The estimation of the diastolic pressure gradient is derived from the transmitral velocity flow curve using the simplified Bernoulli equation $\Delta P = 4v^2$. This estimation is reliable, as shown by the good correlation with invasive measurement using transseptal catheterization.⁴⁴

The use of CWD is preferred to ensure maximal velocities are recorded. When pulsed-wave Doppler is used, the sample volume should be placed at the level or just after leaflet tips.

Doppler gradient is assessed using the apical window in most cases as it allows for parallel alignment of the ultra sound beam and mitral inflow. The ultrasound Doppler beam should be oriented to minimize the intercept angle with mitral flow to avoid underestimation of velocities. Colour Doppler in apical view is useful to identify eccentric diastolic mitral jets that may be encountered in cases of severe deformity of valvular and subvalvular apparatus. In these cases, the Doppler beam is guided by the highest flow velocity zone identified by colour Doppler.

Optimization of gain settings, beam orientation, and a good acoustic window are needed to obtain well-defined contours of the Doppler flow. Maximal and mean mitral gradients are calculated by integrated software using the trace of the Doppler diastolic mitral

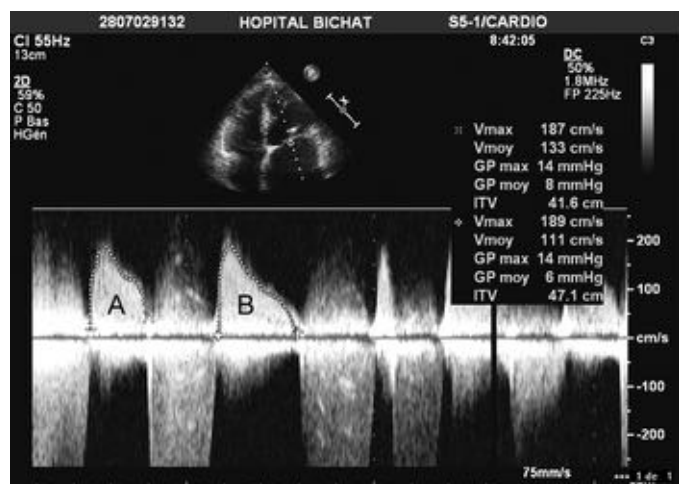


Figure 7 Determination of mean mitral gradient from Doppler diastolic mitral flow in a patient with severe mitral stenosis in atrial fibrillation. Mean gradient varies according to the length of diastole: it is 8 mmHg during a short diastole (A) and 6 mmHg during a longer diastole (B).

flow waveforms on the display screen. Mean gradient is the relevant haemodynamic finding (Figure 7). Maximal gradient is of little interest as it derives from peak mitral velocity, which is influenced by left atrial compliance and LV diastolic function.⁴⁵

Heart rate at which gradients are measured should always be reported. In patients with atrial fibrillation, mean gradient should be calculated as the average of five cycles with the least variation of R-R intervals and as close as possible to normal heart rate.

Mitral gradient, although reliably assessed by Doppler, is not the best marker of the severity of MS since it is dependent on the mitral valve area (MVA) as well as a number of other factors that influence transmitral flow rate, the most important being heart rate, cardiac output, and associated MR.⁴⁶ However, the consistency between mean gradient and other echocardiographic findings should be checked, in particular in patients with poor quality of other variables (especially planimetry of valve area) or when such variables may be affected by additional conditions [i.e. pressure half-time ($T_{1/2}$) in the presence of LV diastolic dysfunction; see below]. In addition, mean mitral gradient has its own prognostic value, in particular following balloon mitral commissurotomy.

B.1.2. MVA Planimetry (Level 1 Recommendation). Theoretically, planimetry using 2D echocardiography of the mitral orifice has the advantage of being a direct measurement of MVA and, unlike other methods, does not involve any hypothesis regarding flow conditions, cardiac chamber compliance, or associated valvular lesions. In practice, planimetry has been shown to have the best correlation with anatomical valve area as assessed on explanted valves.⁴⁷ For these reasons, planimetry is considered as the reference measurement of MVA.^{1,2}

Planimetry measurement is obtained by direct tracing of the mitral orifice, including opened commissures, if applicable, on a parasternal short-axis view. Careful scanning from the apex to the base of the LV is required to ensure that the CSA is measured at the leaflet tips. The measurement plane should be perpendicular to the mitral orifice, which has an elliptical shape (Figure 8).

Gain setting should be just sufficient to visualize the whole contour of the mitral orifice. Excessive gain setting may cause underestimation of valve area, in particular when leaflet tips are dense or calcified.

Image magnification, using the zoom mode, is useful to better delineate the contour of the mitral orifice. The correlation data on planimetry was performed with fundamental imaging and it is unclear whether the use of harmonic imaging improves planimetry measurement.

The optimal timing of the cardiac cycle to measure planimetry is mid-diastole. This is best performed using the cine-loop mode on a frozen image.

It is recommended to perform several different measurements, in particular in patients with atrial fibrillation and in those who have incomplete commissural fusion (moderate MS or after commissurotomy), in whom anatomical valve area may be subject to slight changes according to flow conditions.

Although its accuracy justifies systematic attempts to perform planimetry of MS, it may not be feasible even by experienced echocardiographers when there is a poor acoustic window or severe distortion of valve anatomy, in particular with severe valve calcifications of the leaflet tips. Although the percentage of patients in whom planimetry is not feasible has been reported as low as 5%, this number highly depends on the patient population.⁴⁸ The above-mentioned problems are more frequent in the elderly who represent a significant proportion of patients with MS now in industrialized countries.⁴⁹

Another potential limitation is that the performance of planimetry requires technical expertise. Not all echocardiographers have the opportunity to gain the appropriate experience because of the low prevalence of MS in industrialized countries. The measurement plane must be optimally positioned on the mitral orifice. Recent reports suggested that real-time 3D echo and 3D-guided biplane imaging is useful in optimizing the positioning of the measurement plane and, therefore, improving reproducibility.^{50,51} It also improves the accuracy of planimetry measurement when performed by less experienced echocardiographers.⁵²

In the particular case of degenerative MS, planimetry is difficult and mostly not reliable because of the orifice geometry and calcification present.

B.1.3. Pressure half-time (Level 1 Recommendation). $T_{1/2}$ is defined as the time interval in milliseconds between the maximum mitral gradient in early diastole and the time point where the gradient is half the maximum initial value. The decline of the velocity of diastolic transmitral blood flow is inversely proportional to valve area (cm^2), and MVA is derived using the empirical formula:⁵³

$$\text{MVA} = 220/T_{1/2}$$

$T_{1/2}$ is obtained by tracing the deceleration slope of the E-wave on Doppler spectral display of transmitral flow and valve area is automatically calculated by the integrated software of currently used echo machines (Figure 9). The Doppler signal used is the same as for the measurement of mitral gradient. As for gradient tracing, attention should be paid to the quality of the contour of the Doppler flow, in particular the deceleration slope. The deceleration slope is sometimes bimodal, the decline of mitral flow velocity being more rapid in early diastole than during the following part of the E-wave. In these cases, it is recommended that the deceleration slope in mid-diastole rather than the early deceleration slope be traced (Figure 10).⁵⁴ In the rare patients with a concave shape of the tracing, $T_{1/2}$ measurement may not be feasible. In patients with atrial fibrillation, tracing should avoid mitral flow from short diastoles and average different cardiac cycles.

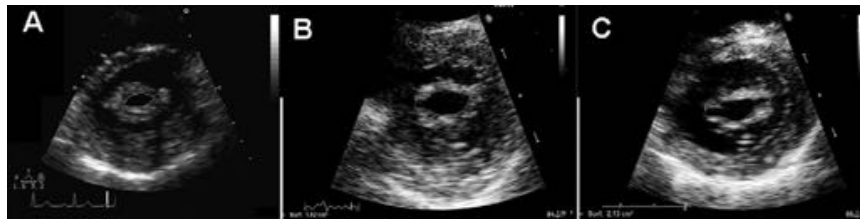

Figure 8 Planimetry of the mitral orifice. Transthoracic echocardiography, parasternal short-axis view. **(A)** Mitral stenosis. Both commissures are fused. Valve area is 1.17 cm². **(B)** Unicommissural opening after balloon mitral commissurotomy. The postero-medial commissure is opened. Valve area is 1.82 cm². **(C)** Bicommisural opening after balloon mitral commissurotomy. Valve area is 2.13 cm².

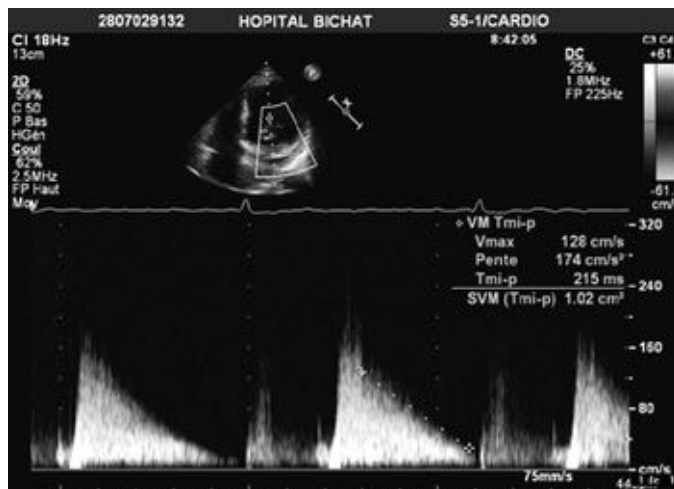

Figure 9 Estimation of mitral valve area using the pressure half-time method in a patient with mitral stenosis in atrial fibrillation. Valve area is 1.02 cm².

The $T_{1/2}$ method is widely used because it is easy to perform, but its limitations should be kept in mind since different factors influence the relationship between $T_{1/2}$ and MVA.

The relationship between the decrease of mean gradient and MVA has been described and empirically validated using initially catheterization data and then Doppler data. However, fluid dynamics principles applied to simulations using mathematical models and in vitro modelling of transmitral valve flow consistently showed that LV diastolic filling rate, which is reflected by the deceleration slope of the E-wave, depends on MVA but also on mitral pressure gradient in early diastole, left atrial compliance, and LV diastolic function (relaxation and compliance).^{53,55} The empirically determined constant of 220 is in fact proportional to the product of net compliance, i.e. the combined compliance of left atrium and LV, and the square root of maximum transmitral gradient in a model that does not take into account active relaxation of LV.⁵⁶ The increase in mean gradient is frequently compensated by a decreased compliance, and this may explain the rather good correlation between $T_{1/2}$ and other measurements of MVA in most series.

However, there are individual variations, in particular when gradient and compliance are subject to important and abrupt changes. This situation occurs immediately after balloon mitral commissurotomy where there may be important discrepancies between the decrease in mitral gradient and the increase in net compliance.⁵⁶ Outside the context of intervention, rapid decrease of mitral velocity flow, i.e. short $T_{1/2}$ can be observed despite severe MS in patients who have a

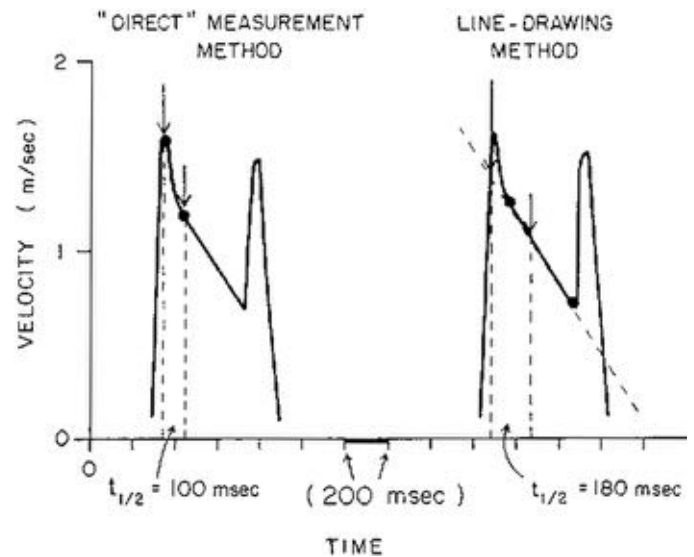


Figure 10 Determination of Doppler pressure half-time ($T_{1/2}$) with a bimodal, non-linear decreasing slope of the E-wave. The deceleration slope should not be traced from the early part (left), but using the extrapolation of the linear mid-portion of the mitral velocity profile (right). (Reproduced from Gonzalez *et al.*⁵⁴).

particularly low left atrial compliance.⁵⁷ $T_{1/2}$ is also shortened in patients who have associated severe AR. The role of impaired LV diastolic function is more difficult to assess because of complex and competing interactions between active relaxation and compliance as regards their impact on diastolic transmitral flow.⁵⁸ Early diastolic deceleration time is prolonged when LV relaxation is impaired, while it tends to be shortened in case of decreased LV compliance.⁵⁹ Impaired LV diastolic function is a likely explanation of the lower reliability of $T_{1/2}$ to assess MVA in the elderly.⁶⁰ This concerns patients with rheumatic MS and, even more, patients with degenerative calcific MS which is a disease of the elderly often associated with AS and hypertension and, thus, impaired diastolic function. Hence, the use of $T_{1/2}$ in degenerative calcific MS may be unreliable and should be avoided.

B.1.4. Continuity equation (Level 2 Recommendation). As in the estimation of AVA, the continuity equation is based on the conservation of mass, stating in this case that the filling volume of diastolic mitral flow is equal to aortic SV.

$$MVA = \pi \left(\frac{D^2}{4} \right) \left(\frac{VTI_{Aortic}}{VTI_{mitral}} \right)$$

where D is the diameter of the LVOT (in cm) and VTI is in cm.⁶¹

Table 5 Assessment of mitral valve anatomy according to the Wilkins score⁶⁴

Grade	Mobility	Thickening	Calcification	Subvalvular Thickening
1	Highly mobile valve with only leaflet tips restricted	Leaflets near normal in thickness (4–5 mm)	A single area of increased echo brightness	Minimal thickening just below the mitral leaflets
2	Leaflet mid and base portions have normal mobility	Midleaflets normal, considerable thickening of margins (5–8 mm)	Scattered areas of brightness confined to leaflet margins	Thickening of chordal structures extending to one-third of the chordal length
3	Valve continues to move forward in diastole, mainly from the base	Thickening extending through the entire leaflet (5–8 mm)	Brightness extending into the mid-portions of the leaflets	Thickening extended to distal third of the chords
4	No or minimal forward movement of the leaflets in diastole	Considerable thickening of all leaflet tissue (>8–10 mm)	Extensive brightness throughout much of the leaflet tissue	Extensive thickening and shortening of all chordal structures extending down to the papillary muscles

The total score is the sum of the four items and ranges between 4 and 16.

Stroke volume can also be estimated from the pulmonary artery; however, this is rarely performed in practice because of limited acoustic windows.

The accuracy and reproducibility of the continuity equation for assessing MVA are hampered by the number of measurements increasing the impact of errors of measurements. The continuity equation cannot be used in cases of atrial fibrillation or associated significant MR or AR.

B.1.5. Proximal isovelocity surface area method (Level 2 Recommendation). The proximal isovelocity surface area method is based on the hemispherical shape of the convergence of diastolic mitral flow on the atrial side of the mitral valve, as shown by colour Doppler. It enables mitral volume flow to be assessed and, thus, to determine MVA by dividing mitral volume flow by the maximum velocity of diastolic mitral flow as assessed by CWD.

$$\text{MVA} = \pi(r^2)(V_{\text{aliasing}})/\text{Peak } V_{\text{Mitral}} \cdot \alpha/180^\circ$$

where r is the radius of the convergence hemisphere (in cm), V_{aliasing} is the aliasing velocity (in cm/s), peak V_{Mitral} the peak CWD velocity of mitral inflow (in cm/s), and α is the opening angle of mitral leaflets relative to flow direction.⁶²

This method can be used in the presence of significant MR. However, it is technically demanding and requires multiple measurements. Its accuracy is impacted upon by uncertainties in the measurement of the radius of the convergence hemisphere, and the opening angle.

The use of colour M-mode improves its accuracy, enabling simultaneous measurement of flow and velocity.⁶²

B.1.6. Other indices of severity. Mitral valve resistance (Level 3 Recommendation) is defined as the ratio of mean mitral gradient to transmitral diastolic flow rate, which is calculated by dividing SV by diastolic filling period. Mitral valve resistance is an alternative measurement of the severity of MS, which has been argued to be less dependent on flow conditions. This is, however, not the case. Mitral valve resistance correlates well with pulmonary artery pressure; however, it has not been shown to have an additional value for assessing the severity of MS as compared with valve area.⁶³

The estimation of pulmonary artery pressure, using Doppler estimation of the systolic gradient between right ventricle (RV) and right atrium, reflects the consequences of MS rather than its severity itself. Although it is advised to check its consistency with mean gradient and

valve area, there may be a wide range of pulmonary artery pressure for a given valve area.^{1,2} Nevertheless, pulmonary artery pressure is critical for clinical decision-making and it is therefore very important to provide this measurement.

B.2. Other echocardiographic factors in the evaluation of mitral stenosis B.2.1. Valve anatomy. Evaluation of anatomy is a major component of echocardiographic assessment of MS because of its implications on the choice of adequate intervention.

Commissural fusion is assessed from the short-axis parasternal view used for planimetry. The degree of commissural fusion is estimated by echo scanning of the valve. However, commissural anatomy may be difficult to assess, in particular in patients with severe valve deformity. Commissures are better visualized using real-time 3D echocardiography.⁵²

Commissural fusion is an important feature to distinguish rheumatic from degenerative MS and to check the consistency of severity measurements. Complete fusion of both commissures generally indicates severe MS. On the other hand, the lack of commissural fusion does not exclude significant MS in degenerative aetiologies or even rheumatic MS, where restenosis after previous commissurotomy may be related to valve rigidity with persistent commissural opening.

Echocardiographic examination also evaluates leaflet thickening and mobility in long-axis parasternal view. Chordal shortening and thickening are assessed using long-axis parasternal and apical views. Increased echo brightness suggests calcification, which is best confirmed by fluoroscopic examination. The report should also mention the homogeneity of impairment of valve anatomy, in particular with regards to commissural areas in parasternal short-axis view.

Impairment of mitral anatomy is expressed in scores combining different components of mitral apparatus or using an overall assessment of valve anatomy^{49,64,65} (Tables 5 and 6). Other scores have been developed, in particular taking into account the location of valve thickening or calcification in relation to commissures; however, they have not been validated in large series. No score has been definitely proven to be superior to another and all have a limited predictive value of the results of balloon mitral commissurotomy, which depends on other clinical and echocardiographic findings.⁶⁴

Table 6 Assessment of mitral valve anatomy according to the Cormier score⁴⁸

Echocardiographic group	Mitral valve anatomy
Group 1	Pliable non-calcified anterior mitral leaflet and mild subvalvular disease (i.e. thin chordae ≥ 10 mm long)
Group 2	Pliable non-calcified anterior mitral leaflet and severe subvalvular disease (i.e. thickened chordae < 10 mm long)
Group 3	Calcification of mitral valve of any extent, as assessed by fluoroscopy, whatever the state of subvalvular apparatus

Thus, the echocardiographic report should include a comprehensive description of valve anatomy and not summarize it using a score alone.

B.2.2. Associated lesions. The quantitation of left atrial enlargement favours 2D echocardiography enabling left atrial area or volume to be evaluated. Standard time-motion measurement lacks accuracy because enlargement does not follow a spherical pattern in most cases. Left atrial spontaneous contrast as assessed by TEE is a better predictor of the thromboembolic risk than left atrial size.⁶⁶ Transoesophageal echocardiography has a much higher sensitivity than the transthoracic approach to diagnose left atrial thrombus, in particular when located in the left atrial appendage.

Associated MR has important implications for the choice of intervention. Quantitation should combine semi-quantitative and quantitative measurements and be particularly careful for regurgitation of intermediate severity since more than mild regurgitation is a relative contraindication for balloon mitral commissurotomy.^{1,2,41} The mechanism of rheumatic MR is restriction of leaflet motion, except after balloon mitral commissurotomy, where leaflet tearing is frequent. The analysis of the mechanism of MR is important in patients presenting with moderate-to-severe regurgitation after balloon mitral commissurotomy. Besides quantitation, a traumatic mechanism is an incentive to consider surgery more frequently than in case of central and/or commissural regurgitation due to valve stiffness without leaflet tear. The presence of MR does not alter the validity of the quantitation of MS, except for the continuity-equation valve area.

Other valve diseases are frequently associated with rheumatic MS. The severity of AS may be underestimated because decreased SV due to MS reduces aortic gradient, thereby highlighting the need for the estimation of AVA. In cases of severe AR, the $T_{1/2}$ method for assessment of MS is not valid.

The analysis of the tricuspid valve should look for signs of involvement of the rheumatic process. More frequently, associated tricuspid disease is functional tricuspid regurgitation (TR). Methods for quantitating TR are not well established and highly sensitive to loading conditions. A diameter of the tricuspid annulus 40 mm seems to be more reliable than quantitation of regurgitation to predict the risk of severe late TR after mitral surgery.^{2,67}

B.3. Stress echocardiography (Level 2 Recommendation) Exercise echocardiography enables mean mitral gradient and systolic pulmonary artery pressure to be assessed during effort. Semi-supine

exercise echocardiography is now preferred to post-exercise echocardiography as it allows for the monitoring of gradient and pulmonary pressure at each step of increasing workload. Haemodynamic changes at effort are highly variable for a given degree of stenosis. Exercise echocardiography is useful in patients whose symptoms are equivocal or discordant with the severity of MS.^{1,2} However, thresholds of mitral gradient and pulmonary artery pressure, as stated in guidelines to consider intervention in asymptomatic patients, rely on low levels of evidence.¹ Estimations of SV and atrioventricular compliance are used for research purposes but have no current clinical application. Dobutamine stress echocardiography has been shown to have prognostic value but is a less physiological approach than exercise echocardiography.^{68,69}

C. How to Grade Mitral Stenosis

Routine evaluation of MS severity should combine measurements of mean gradient and valve area using planimetry and the $T_{1/2}$ method (Tables 7 and 8). In case of discrepancy, the result of planimetry is the reference measurement, except with poor acoustic windows. Assessment of valve area using continuity equation or the proximal isovelocity surface method is not recommended for routine use but may be useful in certain patients when standard measurements are inconclusive.

Associated MR should be accurately quantitated, in particular when moderate or severe. When the severity of both stenosis and regurgitation is balanced, indications for interventions rely more on the consequences of combined stenosis and regurgitation, as assessed by exercise tolerance and mean gradient, than any single individual index of severity of stenosis or regurgitation.² Intervention may be considered when moderate stenosis and moderate regurgitation are combined in symptomatic patients.

Consequences of MS include the quantitation of left atrial size and the estimation of systolic pulmonary artery pressure. The description of valve anatomy is summarized by an echocardiographic score. Rather than to advise the use of a particular scoring system, it is more appropriate that the echocardiographer uses a method that is familiar and includes in the report a detailed description of the impairment of leaflets and subvalvular apparatus, as well as the degree of commissural fusion.

Assessment of other valvular diseases should be particularly careful when intervention is considered. This is particularly true for the quantitation of AS and tricuspid annular enlargement.

Transthoracic echocardiography enables complete evaluation of MS to be performed in most cases. Transoesophageal echocardiography is recommended only when the transthoracic approach is of poor quality, or to detect left atrial thrombosis before balloon mitral commissurotomy or following a thromboembolic event.^{1,2} The use of cardiac catheterization to assess the severity of MS should be restricted to the rare cases where echocardiography is inconclusive or discordant with clinical findings, keeping in mind that the validity of the Gorlin formula is questionable in case of low output or immediately after balloon mitral commissurotomy.^{1,2,70} Right-heart catheterization remains, however, the only investigation enabling pulmonary vascular resistance to be assessed, which may be useful in the case of severe pulmonary hypertension.

The normal MVA is 4.0–5.0 cm². An MVA area of > 1.5 cm² usually does not produce symptoms. As the severity of stenosis increases, cardiac output becomes subnormal at rest and fails to increase during exercise. This is the main reason for considering MS significant when MVA is < 1.5 cm² (Table 9).^{1,2} Indexing on body-surface area is useful to take into account body size. However, no

Table 7 Recommendations for data recording and measurement in routine use for mitral stenosis quantitation

Data element	Recording	Measurement
Planimetry	<ul style="list-style-type: none"> - 2D parasternal short-axis view - determine the smallest orifice by scanning from apex to base - positioning of measurement plan can be oriented by 3D echo - lowest gain setting to visualize the whole mitral orifice 	<ul style="list-style-type: none"> - contour of the inner mitral orifice - include commissures when opened - in mid-diastole (use cine-loop) - average measurements if atrial fibrillation
Mitral flow	<ul style="list-style-type: none"> - continuous-wave Doppler - apical windows often suitable (optimize intercept angle) - adjust gain setting to obtain well-defined flow contour 	<ul style="list-style-type: none"> - mean gradient from the traced contour of the diastolic mitral flow - pressure half-time from the descending slope of the E-wave (mid-diastole slope if not linear) - average measurements if atrial fibrillation
Systolic pulmonary artery pressure	<ul style="list-style-type: none"> - continuous-wave Doppler - multiple acoustic windows to optimize intercept angle 	<ul style="list-style-type: none"> - maximum velocity of tricuspid regurgitant flow - estimation of right atrial pressure according to inferior vena cava diameter
Valve anatomy	<ul style="list-style-type: none"> - parasternal short-axis view - parasternal long-axis view - apical two-chamber view 	<ul style="list-style-type: none"> - valve thickness (maximum and heterogeneity) - commissural fusion - extension and location of localized bright zones (fibrous nodules or calcification) - valve thickness - extension of calcification - valve pliability - subvalvular apparatus (chordal thickening, fusion, or shortening) - subvalvular apparatus (chordal thickening, fusion, or shortening) <p>Detail each component and summarize in a score</p>

threshold of indexed valve area is validated and indexing on body-surface area overestimates the severity of valve stenosis in obese patients.

Ideally, the severity assessment of rheumatic MS should rely mostly on valve area because of the multiple factors influencing other measurements, in particular mean gradient and systolic pulmonary artery pressure. This justifies attempts to estimate MVA using the above-mentioned methods even in patients with severe valve deformity. The values of mean gradient and systolic pulmonary artery pressure are only supportive signs and cannot be considered as surrogate markers of the severity of MS. Abnormal values suggest moderate to severe stenosis. However, normal resting values of pulmonary artery pressure may be observed even in severe MS. In degenerative MS, mean gradient can be used as a marker of severity given the limitations of planimetry and $T_{1/2}$.

Stenosis severity is important, although it is only one of the numerous patient characteristics involved in decision-making for intervention, as detailed in guidelines.^{1,2} Intervention is not considered in patients with MS and MVA >1.5 cm², unless in symptomatic patients of large body size. When MVA is <1.5 cm², the decision to intervene is based on the consequences of valve stenosis (symptoms, atrial fibrillation, pulmonary artery pressure) and the suitability of the patient for balloon mitral commissurotomy. Exercise testing is recommended in patients with MVA, <1.5 cm² who claim to be asymptomatic or with doubtful symptoms.

The impact of echocardiographic findings on the prognosis of MS has mainly been studied after balloon mitral commissurotomy. Multivariate analyses performed in studies reporting a follow-up of at least 10 years identified valve anatomy as a strong predictive factor of event-free survival.⁷¹⁻⁷⁴ Indices of the severity of MS or its haemodynamic consequences immediately after balloon commissurotomy are also predictors of event-free survival, whether it is MVA,^{70,73} mean gradient,^{70,72} and left atrial or pulmonary artery pressure.^{72,73} The degree of MR following balloon mitral commissurotomy and baseline patient characteristics such as age, functional class, and cardiac rhythm are also strong predictors of long-term results of balloon mitral commissurotomy.⁷¹⁻⁷³

Large studies of natural history and of results of surgical commissurotomy predate the current echocardiographic practice and thus do not enable the prognostic value of echocardiographic findings to be assessed.

IV. TRICUSPID STENOSIS

A. Causes and Anatomic Presentation

Tricuspid stenosis (TS) is currently the least common of the valvular stenosis lesions given the low incidence of rheumatic heart disease. In regions where rheumatic heart disease is still prevalent, TS is rarely an isolated disorder; more often, it is accompanied by MS. Other causes of TS include carcinoid syndrome (always combined with TR which

Table 8 Approaches to evaluation of mitral stenosis

Measurement	Units	Formula / Method	Concept	Advantages	Disadvantages
Valve area					
- planimetry by 2D echo	cm ²	tracing mitral orifice using 2D echo	direct measurement of anatomic MVA	- accuracy - independence from other factors	- experience required - not always feasible (poor acoustic window, severe valve calcification)
- pressure half-time	cm ²	$220 / T_{1/2}$	rate of decrease of transmitral flow is inversely proportional to MVA	easy to obtain	dependence on other factors (AR, LA compliance, LV diastolic function...)
- continuity equation	cm ²	$MVA = (CSA_{LVOT} \times VTI_{LVOT}) / VTI_{Mitral}$	volume flows through mitral and aortic orifices are equal	independence from flow conditions	- multiple measurements (sources of errors) - not valid if significant AR or MR
- PISA	cm ²	$MVA = \pi(r^2) \times (V_{aliasing}) / \text{peak } V_{Mitral} \times (a/180^\circ)$	MVA assessed by dividing mitral volume flow by the maximum velocity of diastolic mitral flow	independence from flow conditions	technically difficult
Mean gradient	mm Hg	$\Delta P = \sum 4v^2 / N$	pressure gradient calculated from velocity using the Bernoulli equation	easy to obtain	dependent on heart rate and flow conditions
Systolic pulmonary artery pressure	mm Hg	$sPAP = 4v^2_{Tricuspid} + RA \text{ pressure}$	addition of RA pressure and maximum gradient between RV and RA	obtained in most patients with MS	- arbitrary estimation of RA pressure - no estimation of pulmonary vascular resistance
Mean gradient and systolic pulmonary artery pressure at exercise	mm Hg	$\Delta P = \sum 4v^2 / N$ $sPAP = 4v^2_{Tricuspid} + RA \text{ pressure}$	assessment of gradient and sPAP for increasing workload	incremental value in assessment of tolerance	- experience required - lack of validation for decision-making
Valve resistance	$\frac{\text{dyne}}{\text{sec} \cdot \text{cm}^5}$	$MV_{res} = \frac{P_{Mitral}}{(CSA_{LVOT} \times VTI_{Aortic}) / DFT}$	resistance to flow caused by MS	initially suggested to be less flow-dependent, but not confirmed	no prognostic value no clear threshold for severity no additional value vs. valve area

Level of recommendations: (1) appropriate in all patients (yellow); (2) reasonable when additional information is needed in selected patients (green); and (3) not recommended (blue).

AR, Aortic regurgitation; CSA, cross-sectional area; DFT, diastolic filling time; LA, left atrium; LV, left ventricle; LVOT, left ventricular outflow tract; MR, mitral regurgitation; MS, mitral stenosis; MVA, mitral valve area; MV_{res} , mitral valve resistance; ΔP , gradient; sPAP, systolic pulmonary artery pressure; r , the radius of the convergence hemisphere; RA, right atrium; RV, right ventricle; $T_{1/2}$, pressure half-time; v , velocity; VTI, velocity time integral; N, number of instantaneous measurements.

Table 9 Recommendations for classification of mitral stenosis severity

	Mild	Moderate	Severe
Specific findings			
Valve area (cm ²)	>1.5	1.0–1.5	<1.0
Supportive findings			
Mean gradient (mmHg) ^a	<5	5–10	>10
Pulmonary artery pressure (mmHg)	<30	30–50	>50

^aAt heart rates between 60 and 80 bpm and in sinus rhythm.

is commonly predominant),⁷⁵ rare congenital malformations,^{76–79} valvular or pacemaker endocarditis and pacemaker-induced adhesions,^{80–82} lupus valvulitis,⁸³ and mechanical obstruction by benign or malignant tumors.^{84–87} Most commonly, TS is accompanied by regurgitation so that the higher flows through the valve further increase the transvalvular gradient and contribute to a greater elevation of right atrial pressures.⁸⁸

As with all valve lesions, the initial evaluation starts with an anatomical assessment of the valve by 2D echocardiography using

multiple windows such as parasternal right ventricular inflow, parasternal short axis, apical four-chamber and subcostal four-chamber. One looks for valve thickening and/or calcification, restricted mobility with diastolic doming, reduced leaflet separation at peak opening, and right atrial enlargement (Figure 11).⁸⁹ In carcinoid syndrome, one sees severe immobility of the leaflets, described as a ‘frozen’ appearance (Figure 12). Echocardiography also allows for the detection of valve obstruction by atrial tumours, metastatic lesions, or giant vegetations. Three-dimensional echocardiography can provide better anatomical detail of the relation of the three leaflets to each other and assessment of the orifice area.⁹⁰ Using colour flow Doppler one can appreciate narrowing of the diastolic inflow jet, higher velocities that produce mosaic colour dispersion, and associated valve regurgitation.

B. How to Assess Tricuspid Stenosis

The evaluation of stenosis severity is primarily done using the haemodynamic information provided by CWD. Although there are reports of quantification of orifice area by 3D echocardiography, the methodology is neither standardized nor sufficiently validated to be recommended as a method of choice. The tricuspid inflow velocity is best recorded from either a low parasternal

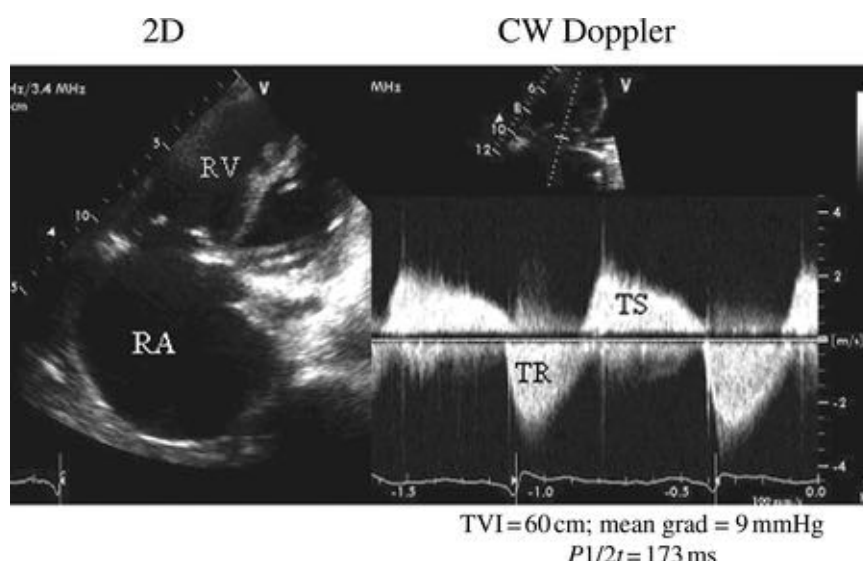


Figure 11 The left panel illustrates a 2D echocardiographic image of a stenotic tricuspid valve obtained in a modified apical four-chamber view during diastole. Note the thickening and diastolic doming of the valve, and the marked enlargement of the right atrium (RA). The right panel shows a CW Doppler recording through the tricuspid valve. Note the elevated peak diastolic velocity of 2 m/s and the systolic tricuspid regurgitation (TR) recording. The diastolic time-velocity integral (TVI), mean gradient (Grad), and pressure half-time ($T_{1/2}$) values are listed.

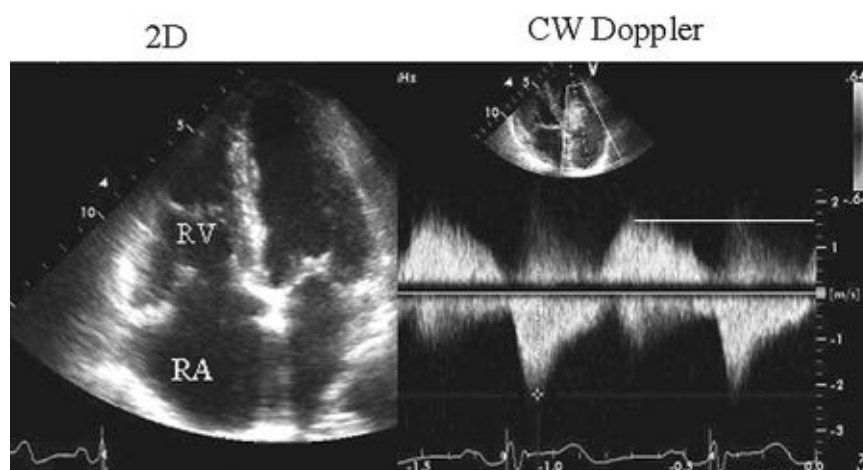


Figure 12 The left panel illustrates a 2D echocardiographic image of a tricuspid valve in a patient with carcinoid syndrome, obtained in an apical four-chamber view during systole. Note the thickening and opened appearance of the valve. The right panel shows a continuous-wave Doppler recording through the tricuspid valve. Note an elevated peak diastolic velocity of 1.6 m/s and the systolic TR recording.

right ventricular inflow view or from the apical four-chamber view. For measurement purposes, all recording should be made at sweep speed of 100 mm/s.⁹⁰ Because tricuspid inflow velocities are affected by respiration, all measurements taken must be averaged throughout the respiratory cycle or recorded at end-expiratory apnea. In patients with atrial fibrillation, measurements from a minimum of five cardiac cycles should be averaged. Whenever possible, it is best to assess the severity of TS at heart rates <100 bpm, preferably between 70 and 80 bpm. As with MS, faster heart rates make it impossible to appreciate the deceleration time (or pressure half-time).

The hallmark of a stenotic valve is an increase in transvalvular velocity recorded by CWD (Figures 11 and 12). Peak inflow velocity through a normal tricuspid valve rarely exceeds 0.7 m/s. Tricuspid

inflow is normally accentuated during inspiration; consequently, with TS, it is common to record peak velocities >1.0 m/s that may approach 2 m/s during inspiration. As a general rule, the mean pressure gradient derived using the $4v^2$ equation is lower in tricuspid than in MS, usually ranging between 2 and 10 mmHg, and averaging around 5 mmHg. Higher gradients may be seen with combined stenosis and regurgitation.⁹¹⁻⁹³

The primary consequence of TS is elevation of right atrial pressure and development of right-sided congestion. Because of the frequent presence of TR, the transvalvular gradient is clinically more relevant for assessment of severity and decision-making than the actual stenotic valve area. In addition, because anatomical valve orifice area is difficult to measure (notwithstanding future developments in 3D), and TR is so frequently present, the typical CWD methods for valve

Table 10 Findings indicative of haemodynamically significant tricuspid stenosis

Specific findings	
Mean pressure gradient	≥ 5 mmHg
Inflow time-velocity integral	> 60 cm
$T_{1/2}$	≥ 190 ms
Valve area by continuity equation ^a	≤ 1 cm ^{2a}
Supportive findings	
Enlarged right atrium \geq moderate	
Dilated inferior vena cava	

^aStroke volume derived from left or right ventricular outflow. In the presence of more than mild TR, the derived valve area will be underestimated. Nevertheless, a value ≤ 1 cm² implies a significant haemodynamic burden imposed by the combined lesion.

area determination are not very accurate. The pressure half-time method ($T_{1/2}$) has been applied in a manner analogous to MS. Some authors have used the same constant of 220, while others have proposed a constant of 190 with valve area determined as: $190/T_{1/2}$.⁹³ Although validation studies with TS are less than those with MS, valve area by the $T_{1/2}$ method may be less accurate than in MS. This is probably due to differences in atrioventricular compliance between the right and left side, and the influence of right ventricular relaxation, respiration, and TR on the pressure half-time. However, as a general rule, a longer $T_{1/2}$ implies a greater TS severity with values > 190 frequently associated with significant (or critical) stenosis.

In theory, the continuity equation should provide a robust method for determining the effective valve area as SV divided by the tricuspid inflow VTI as recorded with CWD.⁹⁴ The main limitation of the method is obtaining an accurate measurement of the inflow volume passing through the tricuspid valve. In the absence of significant TR, one can use the SV obtained from either the left or right ventricular outflow; a valve area of ≤ 1 cm² is considered indicative of severe TS. However, as severity of TR increases, valve area is progressively underestimated by this method. Nevertheless, a value ≤ 1 cm², although it is not accounting for the additional regurgitant volume, may still be indicative of a significant hemodynamic burden induced by the combined lesion.

C. How to Grade Tricuspid Stenosis

From a clinical standpoint, the importance of an accurate assessment of TS is to be able to recognize patients with haemodynamically significant stenosis in whom a surgical- or catheter-based procedure may be necessary to relieve symptoms of right-sided failure. In the presence of anatomic evidence by 2D echo of TS, the findings listed in Table 10 are consistent with significant stenosis with or without regurgitation.

V. PULMONIC STENOSIS

Echocardiography plays a major role in the assessment and management of pulmonary valve stenosis.⁹⁵ It is useful in detecting the site of the stenosis, quantifying severity, determining the cause of the stenosis, and is essential in determining an appropriate management strategy.⁹⁶ Ancillary findings with pulmonary stenosis such as right ventricular hypertrophy may also be detected and assessed. Although the majority of pulmonary stenosis is valvular, narrowing of the right

ventricular outflow tract (RVOT) below the valve from concurrent right ventricular hypertrophy may occur as may narrowing of the pulmonary artery sinotubular junction above the valve.

A. Causes and Anatomic Presentation

Pulmonary stenosis is almost always congenital in origin. The normal pulmonary valve is trileaflet. The congenitally stenotic valve may be trileaflet, bicuspid, unicuspid, or dysplastic.⁹⁷

Acquired stenosis of the pulmonary valve is very uncommon. Rheumatic pulmonary stenosis is rare even when the valve is affected by the rheumatic process.⁹⁸ Carcinoid disease is the commonest cause of acquired pulmonary valve disease (combined stenosis and regurgitation with usually predominant regurgitation) and this may be sufficiently severe to require prosthetic replacement. Various tumors may compress the RV outflow tract leading to functional pulmonary stenosis. These tumors may arise from within the heart or associated vasculature or be external to the heart and compress from without.^{99,100} Pulmonary valve stenosis may also occur as part of more complex congenital lesions such as tetralogy of Fallot, complete atrioventricular canal, double outlet RV, and univentricular heart. Peripheral pulmonary artery stenosis may co-exist with valvular pulmonary stenosis such as in Noonan's syndrome and Williams syndrome.

Stenosis below (proximal to) the pulmonary valve may result from a number of causes, both congenital and acquired. Congenital ventricular septal defect (VSD) may also be associated with RV outflow tract obstruction secondary to development of obstructive midcavitary or infundibular muscle bundles (double chamber RV) or in rare cases as a result of the jet lesion produced by the VSD in this area. Severe right ventricular hypertrophy of any cause but in some cases caused by valvular pulmonary stenosis itself may be responsible for narrowing of the infundibular area below the pulmonary valve. Iatrogenic causes include prior surgery or intervention on this area. Other causes include hypertrophic or infiltrative processes such as hypertrophic obstructive cardiomyopathy or glycogen storage disorders and compression from a tumour or vascular structure.

Stenosis of the pulmonary artery above the valve (distal to the valve) may occur in the main pulmonary trunk at the bifurcation, or more distally in the branch vessels. In rare instances, a membrane just above the valve may cause stenosis. Pulmonary artery stenosis may occur as an isolated finding without other malformations.

B. How to Grade Pulmonary Stenosis

Pulmonic stenosis severity Quantitative assessment of pulmonary stenosis severity is based mainly on the transpulmonary pressure gradient. Calculation of pulmonic valve area by planimetry is not possible since the required image plane is in general not available. Continuity equation or proximal isovelocity surface area method, although feasible in principle, has not been validated in pulmonary stenosis and is rarely performed.

B.1.1. Pressure gradient. The estimation of the systolic pressure gradient is derived from the transpulmonary velocity flow curve using the simplified Bernoulli equation $\Delta P = 4v^2$. This estimation is reliable, as shown by the good correlation with invasive measurement using cardiac catheterization.¹⁰¹ Continuous-wave Doppler is used to assess the severity when even mild stenosis is present. It is important to line up the Doppler sample volume parallel to the flow with the aid of colour flow mapping where appropriate. In adults, this is usually most readily performed from a parasternal short-axis view but in children and in some adults the highest gradients may be found from

Table 11 Grading of pulmonary stenosis

	Mild	Moderate	Severe
Peak velocity (m/s)	<3	3–4	>4
Peak gradient (mmHg)	<36	36–64	>64

the subcostal window. A modified apical five-chamber view may also be used where the transducer is angled clockwise to bring in the RV outflow tract. Ideally, the highest velocity in multiple views should be used for the determination.^{102,103}

In most instances of valvular pulmonary stenosis, the modified Bernoulli equation works well and there is no need to account for the proximal velocity as this is usually, 1 m/s. There are exceptions to this, however. In the setting of subvalvular or infundibular stenosis and pulmonary stenosis as part of a congenital syndrome or as a result of RV hypertrophy, the presence of two stenoses in series may make it impossible to ascertain precisely the individual contribution of each. In addition, such stenoses in series may cause significant PR resulting in a higher Doppler gradient compared with the net pressure drop across both stenoses.¹⁰⁴ Pulsed-wave Doppler may be useful to detect the sites of varying levels of obstruction in the outflow tract and in lesser degrees of obstruction may allow a full evaluation of it. Muscular infundibular obstruction is frequently characterized by a late peaking systolic jet that appears 'dagger shaped', reflecting the dynamic nature of the obstruction; this pattern can be useful in separating dynamic muscular obstruction from fixed valvular obstruction, where the peak velocity is generated early in systole.

In certain situations, TEE may allow a more accurate assessment of the pulmonary valve and RVOT. The pulmonary valve may be identified from a mid-esophageal window at varying transducer positions from 50 to 90, anterior to the aortic valve. The RVOT is often well seen in this view. It is in general impossible to line up CW to accurately ascertain maximal flow velocity. Other windows in which the pulmonary outflow tract may be interrogated include the deep transgastric view in which by appropriate torquing of the transducer, the RV inflow and outflow may be appreciated in a single image. This view can allow accurate alignment of the Doppler beam with the area of subvalvar/valvular stenosis through the RV outflow tract.

In pulmonary valve stenosis, the pressure gradient across the valve is used to ascertain severity of the lesion more so than in left-sided valve conditions due in part to the difficulty in obtaining an accurate assessment of pulmonary valve area. The following definitions of severity have been defined in the 2006 American College of Cardiology/American Heart Association (ACC/AHA) guidelines on the management of valvular heart disease:¹

Severe stenosis (Table 11): a peak jet velocity >4 m/s (peak gradient >64 mmHg) Moderate stenosis: peak jet velocity of 3–4 m/s (peak gradient 36–64 mmHg)

Mild stenosis: peak jet velocity is: <3 m/s (peak gradient less than 36 mmHg).

In determining the need for intervention, no specific Doppler gradients have been agreed on.

Severity of pulmonary stenosis using Doppler gradients has been based on catheterization data with demonstration of reasonable correlation between instantaneous peak Doppler gradients and peak-to-peak gradients obtained by catheterization. Typically though,

Doppler peak gradients tend to be higher than peak-to-peak catheterization gradients.¹⁰² Doppler mean gradient has been shown in one study to correlate better with peak-to-peak catheterization gradient but is not commonly used.¹⁰⁵

B.1.2. Other indices of severity. A useful index of severity is to determine the RV systolic pressure in patients with pulmonary stenosis from the tricuspid regurgitant velocity and the addition of an estimate of right atrial pressure. The pulmonary artery systolic pressure should be RV systolic pressure – pulmonary valve pressure gradient. In settings where there are multiple stenoses in the RV outflow tract or in the more peripheral pulmonary tree (sometimes associated with valvular pulmonary stenosis), the failure of the measured pulmonary valve gradient to account for much of the RV systolic pressure may be a clue for the presence of alternative stenoses.

B.1.3. Valve anatomy. Evaluation of anatomy is important in defining where the stenosis is maximal, as discussed above. Valve morphology is often evident especially the thin mobile leaflets seen with the dome-shaped valve. Dysplastic leaflets move little and are rarely associated with the post-stenotic dilatation common in dome-shaped leaflets. Calcification of the valve is relatively rare so the valve appearance does not play a huge role in decisions for balloon valvuloplasty. However, the size of the pulmonary annulus should be measured in order to define the optimal balloon size for successful dilatation of the valve.¹⁰⁶

B.1.4. Associated lesions. Pulmonic stenosis especially when severe may be associated with right ventricular hypertrophy, eventually right ventricular enlargement, and right atrial enlargement. Given the unusual shape of the RV and its proximity to the chest wall, accurate estimation of RV hypertrophy and enlargement may be difficult. The parasternal long-axis and subcostal long-axis views are often best in assessing RV hypertrophy. The normal thickness of the RV is ~2–3 mm but given the difficulties in estimating thickness, a thickness of >5mm is usually considered abnormal. RV enlargement is typically assessed in the apical or subcostal four-chamber view.^{107–109}

As described above, pulmonary stenosis may form part of other syndromes or may be associated with other congenital lesions. Dilatation of the pulmonary artery beyond the valve is common and is due to weakness in the arterial wall in a manner analogous to bicuspid aortic valve and is not necessarily commensurate with the degree of obstruction. Detection of other lesions such as infundibular stenosis, VSD, or tetralogy of Fallot is all important in the assessment of these patients.

ACKNOWLEDGEMENTS

We would like to thank Peter Frommelt MD, for his review of the pulmonary stenosis section and Gloria Healy for her technical assistance.

REFERENCES

1. Bonow RO, Carabello BA, Chatterjee K, de Leon CC Jr, Faxon DP, Freed MD et al. ACC/AHA 2006 guidelines for the management of patients with valvular heart disease: a report of the American College of Cardiology/American Heart Association Task Force on Practice Guidelines (writing Committee to Revise the 1998 guidelines for the management of patients with valvular heart disease) developed in collaboration with the Society of Cardiovascular Anesthesiologists endorsed by the Society for Cardiovascular Angiography and Interventions and the Society of Thoracic Surgeons. *J Am Coll Cardiol* 2006;48:e1–148.

2. Vahanian A, Baumgartner H, Bax J, Butchart E, Dion R, Filippatos G et al. Guidelines on the management of valvular heart disease: The Task Force on the Management of Valvular Heart Disease of the European Society of Cardiology. *Eur Heart J* 2007;28:230-68.
3. Chambers J, Bach D, Dumesnil J, Otto C, Shah P, Thomas J. Crossing the aortic valve in severe aortic stenosis: no longer acceptable? *J Heart Valve Dis* 2004;13:344-6.
4. Roberts WC, Ko JM. Frequency by decades of unicuspid, bicuspid, and tricuspid aortic valves in adults having isolated aortic valve replacement for aortic stenosis, with or without associated aortic regurgitation. *Circulation* 2005;111:920-5.
5. Nistri S, Sorbo MD, Marin M, Palisi M, Scognamiglio R, Thiene G. Aortic root dilatation in young men with normally functioning bicuspid aortic valves. *Heart* 1999;82:19-22.
6. Schaefer BM, Lewin MB, Stout KK, Byers PH, Otto CM. Usefulness of bicuspid aortic valve phenotype to predict elastic properties of the ascending aorta. *Am J Cardiol* 2007;99:686-90.
7. Rosenhek R, Binder T, Porenta G, Lang I, Christ G, Schemper M et al. Predictors of outcome in severe, asymptomatic aortic stenosis. *N Engl J Med* 2000;343:611-7.
8. Currie PJ, Seward JB, Reeder GS, Vlietstra RE, Bresnahan DR, Bresnahan JF et al. Continuous-wave Doppler echocardiographic assessment of severity of calcific aortic stenosis: a simultaneous Doppler-catheter correlative study in 100 adult patients. *Circulation* 1985;71: 1162-9.
9. Smith MD, Kwan OL, DeMaria AN. Value and limitations of continuous-wave Doppler echocardiography in estimating severity of valvular stenosis. *J Am Med Assoc* 1986;255:3145-51.
10. Burwash IG, Forbes AD, Sadahiro M, Verrier ED, Pearlman AS, Thomas R et al. Echocardiographic volume flow and stenosis severity measures with changing flow rate in aortic stenosis. *Am J Physiol* 1993;265(5 Pt 2):H1734-43.
11. Baumgartner H, Stefanelli T, Niederberger J, Schima H, Maurer G. 'Overestimation' of catheter gradients by Doppler ultrasound in patients with aortic stenosis: a predictable manifestation of pressure recovery. *J Am Coll Cardiol* 1999;33:1655-61.
12. Otto CM, Burwash IG, Legget ME, Munt BI, Fujioka M, Healy NL et al. Prospective study of asymptomatic valvular aortic stenosis. Clinical, echocardiographic, and exercise predictors of outcome. *Circulation* 1997;95:2262-70.
13. Pellikka PA, Sarano ME, Nishimura RA, Malouf JF, Bailey KR, Scott CG et al. Outcome of 622 adults with asymptomatic, hemodynamically significant aortic stenosis during prolonged follow-up. *Circulation* 2005;111:3290-5.
14. Zoghbi WA, Farmer KL, Soto JG, Nelson JG, Quinones MA. Accurate non-invasive quantification of stenotic aortic valve area by Doppler echocardiography. *Circulation* 1986;73:452-9.
15. Otto CM, Pearlman AS, Comess KA, Reamer RP, Janko CL, Huntsman LL et al. Determination of the stenotic aortic valve area in adults using Doppler echocardiography. *J Am Coll Cardiol* 1986;7:509-17.
16. Baumgartner H, Kratzer H, Helmreich G, Kuehn P. Determination of aortic valve area by Doppler echocardiography using the continuity equation: a critical evaluation. *Cardiology* 1990;77:101-11.
17. Evangelista A, Garcia-Dorado D, Garcia del Castillo H, Gonzalez-Alujas T, Soler-Soler J. Cardiac index quantification by Doppler ultrasound in patients without left ventricular outflow tract abnormalities. *J Am Coll Cardiol* 1995;25:710-6.
18. Oh JK, Taliencio CP, Holmes DR Jr, Reeder GS, Bailey KR, Seward JB et al. Prediction of the severity of aortic stenosis by Doppler aortic valve area determination: prospective Doppler-catheterization correlation in 100 patients. *J Am Coll Cardiol* 1988;11:1227-34.
19. Rosenhek R, Klaar U, Schemper M, Scholten C, Heger M, Gabriel H et al. Mild and moderate aortic stenosis. Natural history and risk stratification by echocardiography. *Eur Heart J* 2004;25:199-205.
20. Gilon D, Cape EG, Handschumacher MD, Song JK, Solheim J, VanAuker M et al. Effect of three-dimensional valve shape on the hemodynamics of aortic stenosis: three-dimensional echocardiographic stereolithography and patient studies. *J Am Coll Cardiol* 2002;40: 1479-86.
21. Otto CM, Pearlman AS, Kraft CD, Miyake-Hull CY, Burwash IG, Gardner CJ. Physiologic changes with maximal exercise in asymptomatic valvular aortic stenosis assessed by Doppler echocardiography. *J Am Coll Cardiol* 1992;20:1160-7.
22. Lancellotti P, Lebois F, Simon M, Tombeux C, Chauvel C, Pierard LA. Prognostic importance of quantitative exercise Doppler echocardiography in asymptomatic valvular aortic stenosis. *Circulation* 2005;112(9 Suppl):I377-82.
23. Otto CM, Pearlman AS. Doppler echocardiography in adults with symptomatic aortic stenosis. Diagnostic utility and cost-effectiveness. *Arch Intern Med* 1988;148:2553-60.
24. Okura H, Yoshida K, Hozumi T, Akasaka T, Yoshikawa J. Planimetry and transthoracic two-dimensional echocardiography in noninvasive assessment of aortic valve area in patients with valvular aortic stenosis. *J Am Coll Cardiol* 1997;30:753-9.
25. Cormier B, Iung B, Porte JM, Barbant S, Vahanian A. Value of multi-plane transesophageal echocardiography in determining aortic valve area in aortic stenosis. *Am J Cardiol* 1996;77:882-5.
26. Goland S, Trento A, Iida K, Czer LS, De Robertis M, Naqvi TZ et al. Assessment of aortic stenosis by three-dimensional echocardiography: an accurate and novel approach. *Heart* 2007;93:801-7.
27. Bermejo J, Odreman R, Feijoo J, Moreno MM, Gomez-Moreno P, Garcia-Fernandez MA. Clinical efficacy of Doppler-echocardiographic indices of aortic valve stenosis: a comparative test-based analysis of outcome. *J Am Coll Cardiol* 2003;41:142-51.
28. Bermejo J, Garcia-Fernandez MA, Torrecilla EG, Bueno H, Moreno MM, San Roman D et al. Effects of dobutamine on Doppler echocardiographic indexes of aortic stenosis. *J Am Coll Cardiol* 1996;28: 1206-13.
29. Burwash IG, Thomas DD, Sadahiro M, Pearlman AS, Verrier ED, Thomas R et al. Dependence of Gorlin formula and continuity equation valve areas on transvalvular volume flow rate in valvular aortic stenosis. *Circulation* 1994;89:827-35.
30. Blais C, Burwash IG, Mundigler G, Dumesnil JG, Loho N, Rader F et al. Projected valve area at normal flow rate improves the assessment of stenosis severity in patients with low-flow, low-gradient aortic stenosis: the multicenter TOPAS (Truly or Pseudo-Severe Aortic Stenosis) study. *Circulation* 2006;113:711-21.
31. Briand M, Dumesnil JG, Kadem L, Tongue AG, Rieu R, Garcia D et al. Reduced systemic arterial compliance impacts significantly on left ventricular afterload and function in aortic stenosis: implications for diagnosis and treatment. *J Am Coll Cardiol* 2005;46:291-8.
32. Niederberger J, Schima H, Maurer G, Baumgartner H. Importance of pressure recovery for the assessment of aortic stenosis by Doppler ultrasound. Role of aortic size, aortic valve area, and direction of the stenotic jet in vitro. *Circulation* 1996;94:1934-40.
33. Monin JL, Monchi M, Gest V, Duval-Moulin AM, Dubois-Rande JL, Gueret P. Aortic stenosis with severe left ventricular dysfunction and low transvalvular pressure gradients: risk stratification by low-dose dobutamine echocardiography. *J Am Coll Cardiol* 2001;37:2101-7.
34. Nishimura RA, Grantham JA, Connolly HM, Schaff HV, Higano ST, Holmes DR Jr. Low-output, low-gradient aortic stenosis in patients with depressed left ventricular systolic function: the clinical utility of the dobutamine challenge in the catheterization laboratory. *Circulation* 2002;106:809-13.
35. Takeda S, Rimington H, Chambers J. The relation between transaortic pressure difference and flow during dobutamine stress echocardiography in patients with aortic stenosis. *Heart* 1999;82:11-4.
36. Monin JL, Quere JP, Monchi M, Petit H, Baleyraud S, Chauvel C et al. Low-gradient aortic stenosis: operative risk stratification and predictors for long-term outcome: a multicenter study using dobutamine stress hemodynamics. *Circulation* 2003;108:319-24.
37. Mascherbauer J, Fuchs C, Stoiber M, Schima H, Pernicka E, Maurer G et al. Systemic pressure does not directly affect pressure gradient and valve area estimates in aortic stenosis in vitro. *Eur Heart J* 2008;29: 2049-57.

38. Kadem L, Dumesnil JG, Rieu R, Durand LG, Garcia D, Pibarot P. Impact of systemic hypertension on the assessment of aortic stenosis. *Heart* 2005;91:354-61.
39. Little SH, Chan KL, Burwash IG. Impact of blood pressure on the Doppler echocardiographic assessment of severity of aortic stenosis. *Heart* 2007;93:848-55.
40. Otto CM. Valvular aortic stenosis: disease severity and timing of intervention. *J Am Coll Cardiol* 2006;47:2141-51.
41. Zoghbi WA, Enriquez-Sarano M, Foster E, Grayburn PA, Kraft CD, Levine RA et al. Recommendations for evaluation of the severity of native valvular regurgitation with two-dimensional and Doppler echocardiography. *J Am Soc Echocardiogr* 2003;16:777-802.
42. Iung B, Baron G, Butchart EG, Delahaye F, Gohlke-Barwolf C, Levang OW et al. A prospective survey of patients with valvular heart disease in Europe: The Euro Heart Survey on Valvular Heart Disease. *Eur Heart J* 2003;24:1231-43.
43. Marijon E, Ou P, Celermajer DS, Ferreira B, Mocumbi AO, Jani D et al. Prevalence of rheumatic heart disease detected by echocardiographic screening. *N Engl J Med* 2007;357:470-6.
44. Nishimura RA, Rihal CS, Tajik AJ, Holmes DR Jr. Accurate measurement of the transmitral gradient in patients with mitral stenosis: a simultaneous catheterization and Doppler echocardiographic study. *J Am Coll Cardiol* 1994;24:152-8.
45. Thomas JD, Newell JB, Choong CY, Weyman AE. Physical and physiological determinants of transmitral velocity: numerical analysis. *Am J Physiol* 1991;260(5 Pt 2):H1718-31.
46. Rahimtoola SH, Durairaj A, Mehra A, Nuno I. Current evaluation and management of patients with mitral stenosis. *Circulation* 2002;106:1183-8.
47. Faletta F, Pezzano A Jr, Fusco R, Mantero A, Corno R, Crivellaro W et al. Measurement of mitral valve area in mitral stenosis: four echocardiographic methods compared with direct measurement of anatomic orifices. *J Am Coll Cardiol* 1996;28:1190-7.
48. Iung B, Cormier B, Ducimetiere P, Porte JM, Nallet O, Michel PL et al. Immediate results of percutaneous mitral commissurotomy. A predictive model on a series of 1514 patients. *Circulation* 1996;94:2124-30.
49. Shaw TR, Sutaria N, Prendergast B. Clinical and haemodynamic profiles of young, middle aged, and elderly patients with mitral stenosis undergoing mitral balloon valvotomy. *Heart* 2003;89:1430-6.
50. Zamorano J, Cordeiro P, Sugeng L, Perez de Isla L, Weinert L, Macaya C et al. Real-time three-dimensional echocardiography for rheumatic mitral valve stenosis evaluation: an accurate and novel approach. *J Am Coll Cardiol* 2004;43:2091-6.
51. Sebag IA, Morgan JG, Handschumacher MD, Marshall JE, Nesta F, Hung J et al. Usefulness of three-dimensionally guided assessment of mitral stenosis using matrix-array ultrasound. *Am J Cardiol* 2005;96:1151-6.
52. Messika-Zeitoun D, Brochet E, Holmin C, Rosenbaum D, Cormier B, Serfaty JM et al. Three-dimensional evaluation of the mitral valve area and commissural opening before and after percutaneous mitral commissurotomy in patients with mitral stenosis. *Eur Heart J* 2007;28:72-9.
53. Thomas JD, Weyman AE. Doppler mitral pressure half-time: a clinical tool in search of theoretical justification. *J Am Coll Cardiol* 1987;10:923-9.
54. Gonzalez MA, Child JS, Krivokapich J. Comparison of two-dimensional and Doppler echocardiography and intracardiac hemodynamics for quantification of mitral stenosis. *Am J Cardiol* 1987;60:327-32.
55. Thomas JD, Weyman AE. Fluid dynamics model of mitral valve flow: description with in vitro validation. *J Am Coll Cardiol* 1989;13:221-33.
56. Thomas JD, Wilkins GT, Choong CY, Abascal VM, Palacios IF, Block PC et al. Inaccuracy of mitral pressure half-time immediately after percutaneous mitral valvotomy. Dependence on transmitral gradient and left atrial and ventricular compliance. *Circulation* 1988;78:980-93.
57. Schwammenthal E, Vered Z, Agranat O, Kaplinsky E, Rabinowitz B, Feinberg MS. Impact of atrioventricular compliance on pulmonary artery pressure in mitral stenosis: an exercise echocardiographic study. *Circulation* 2000;102:2378-84.
58. Flachskampf FA, Weyman AE, Guerrero JL, Thomas JD. Calculation of atrioventricular compliance from the mitral flow profile: analytic and in vitro study. *J Am Coll Cardiol* 1992;19:998-1004.
59. Karp K, Teien D, Bjerle P, Eriksson P. Reassessment of valve area determinations in mitral stenosis by the pressure half-time method: impact of left ventricular stiffness and peak diastolic pressure difference. *J Am Coll Cardiol* 1989;13:594-9.
60. Messika-Zeitoun D, Meizels A, Cachier A, Scheuble A, Fondard O, Brochet E et al. Echocardiographic evaluation of the mitral valve area before and after percutaneous mitral commissurotomy: the pressure half-time method revisited. *J Am Soc Echocardiogr* 2005;18:1409-14.
61. Nakatani S, Masuyama T, Kodama K, Kitabatake A, Fujii K, Kamada T. Value and limitations of Doppler echocardiography in the quantification of stenotic mitral valve area: comparison of the pressure half-time and the continuity equation methods. *Circulation* 1988;77:78-85.
62. Messika-Zeitoun D, Fung Yiu S, Cormier B, Iung B, Scott IC, Vahanian A et al. Sequential assessment of mitral valve area during diastole using colour M-mode flow convergence analysis: new insights into mitral stenosis physiology. *Eur Heart J* 2003;24:1244-53.
63. Izgi C, Ozdemir N, Cevik C, Ozveren O, Bakal RB, Kaymaz C et al. Mitral valve resistance as a determinant of resting and stress pulmonary artery pressure in patients with mitral stenosis: a dobutamine stress study. *J Am Soc Echocardiogr* 2007;20:1160-6.
64. Wilkins GT, Weyman AE, Abascal VM, Block PC, Palacios IF. Percutaneous balloon dilatation of the mitral valve: an analysis of echocardiographic variables related to outcome and the mechanism of dilatation. *Br Heart J* 1988;60:299-308.
65. Vahanian A, Palacios IF. Percutaneous approaches to valvular disease. *Circulation* 2004;109:1572-9.
66. Black IW, Hopkins AP, Lee LC, Walsh WF. Left atrial spontaneous echo contrast: a clinical and echocardiographic analysis. *J Am Coll Cardiol* 1991;18:398-404.
67. Dreyfus GD, Corbi PJ, Chan KM, Bahrami T. Secondary tricuspid regurgitation or dilatation: which should be the criteria for surgical repair? *Ann Thorac Surg* 2005;79:127-32.
68. Hecker SL, Zabalgaitia M, Ashline P, Oneschuk L, O'Rourke RA, Herrera CJ. Comparison of exercise and dobutamine stress echocardiography in assessing mitral stenosis. *Am J Cardiol* 1997;80:1374-7.
69. Reis G, Motta MS, Barbosa MM, Esteves WA, Souza SF, Bocchi EA. Dobutamine stress echocardiography for noninvasive assessment and risk stratification of patients with rheumatic mitral stenosis. *J Am Coll Cardiol* 2004;43:393-401.
70. Segal J, Lerner DJ, Miller DC, Mitchell RS, Alderman EA, Popp RL. When should Doppler-determined valve area be better than the Gorlin formula?: variation in hydraulic constants in low flow states. *J Am Coll Cardiol* 1987;9:1294-305.
71. Iung B, Garbarz E, Michaud P, Helou S, Farah B, Berdah P et al. Late results of percutaneous mitral commissurotomy in a series of 1024 patients. Analysis of late clinical deterioration: frequency, anatomic findings, and predictive factors. *Circulation* 1999;99:3272-8.
72. Palacios IF, Sanchez PL, Harrell LC, Weyman AE, Block PC. Which patients benefit from percutaneous mitral balloon valvuloplasty? Prevalvalvuloplasty and postvalvuloplasty variables that predict long-term outcome. *Circulation* 2002;105:1465-71.
73. Ben-Farhat M, Betbout F, Gamra H, Maatouk F, Ben-Hamda K, Abdel-laoui M et al. Predictors of long-term event-free survival and of freedom from restenosis after percutaneous balloon mitral commissurotomy. *Am Heart J* 2001;142:1072-9.
74. Fawzy ME, Shoukri M, Al Buraiki J, Hassan W, El Widaal H, Kharabsheh S et al. Seventeen years' clinical and echocardiographic follow up of mitral balloon valvuloplasty in 520 patients, and predictors of long-term outcome. *J Heart Valve Dis* 2007;16:454-60.
75. Thatipelli MR, Uber PA, Mehra MR. Isolated tricuspid stenosis and heart failure: a focus on carcinoid heart disease. *Congest Heart Fail* 2003;9:294-6.

76. Ootaki Y, Yamaguchi M, Yoshimura N, Tsukuda K. Congenital heart disease with hypereosinophilic syndrome. *Pediatr Cardiol* 2003;24:608-10.
77. Cohen ML, Spray T, Gutierrez F, Barzilai B, Bauwens D. Congenital tricuspid valve stenosis with atrial septal defect and left anterior fascicular block. *Clin Cardiol* 1990;13:497-9.
78. Mehta V, Sengupta PP, Banerjee A, Arora R, Datt V. Congenital tricuspid stenosis and membranous right ventricular outflow tract obstruction in an adult. *Ann Card Anaesth* 2003;6:152-5.
79. Dervanian P, Mace L, Bucari S, Folliguet TA, Grinda JM, Neveux JY. Valved conduit bypass for extensively calcified tricuspid valve stenosis. *Ann Thorac Surg* 1995;60:450-2.
80. Saito T, Horimi H, Hasegawa T, Kamoshida T. Isolated tricuspid valve stenosis caused by infective endocarditis in an adult: report of a case. *Surg Today* 1993;23:1081-4.
81. Old WD, Paulsen W, Lewis SA, Nixon JV. Pacemaker lead-induced tricuspid stenosis: diagnosis by Doppler echocardiography. *Am Heart J* 1989;117:1165-7.
82. Taira K, Suzuki A, Fujino A, Watanabe T, Ogyu A, Ashikawa K. Tricuspid valve stenosis related to subvalvular adhesion of pacemaker lead: a case report. *J Cardiol* 2006;47:301-6.
83. Ames DE, Asherson RA, Coltart JD, Vassilikos V, Jones JK, Hughes GR. Systemic lupus erythematosus complicated by tricuspid stenosis and regurgitation: successful treatment by valve transplantation. *Ann Rheum Dis* 1992;51:120-2.
84. Kuralay E, Cingoz F, Gunay C, Demirkilic U, Tatar H. Huge right atrial myxoma causing fixed tricuspid stenosis with constitutional symptoms. *J Card Surg* 2003;18:550-3.
85. Uribe-Etxebarria N, Voces R, Rodriguez MA, Llorente A, Perez P, Aramendi JI. Reversible tricuspid valve stenosis due to a metastatic dissemination of a noncardiac sarcoma. *Ann Thorac Surg* 2005;80:e1-2.
86. Chrissos DN, Stougiannos PN, Mytas DZ, Katsaros AA, Andrikopoulos GK, Kallikazaros IE. Multiple cardiac metastases from a malignant melanoma. *Eur J Echocardiogr* 2008;9:391-2.
87. Nishida H, Grooters RK, Coster D, Soltanzadeh H, Thieman KC. Metastatic right atrial tumor in colon cancer with superior vena cava syndrome and tricuspid obstruction. *Heart Vessels* 1991;6:125-7.
88. Yousof AM, Shafei MZ, Endrys G, Khan N, Simo M, Cherian G. Tricuspid stenosis and regurgitation in rheumatic heart disease: a prospective cardiac catheterization study in 525 patients. *Am Heart J* 1985;110(1 Pt 1):60-4.
89. Pearlman AS. Role of echocardiography in the diagnosis and evaluation of severity of mitral and tricuspid stenosis. *Circulation* 1991;84(3 Suppl): 1193-7.
90. Pothineni KR, Duncan K, Yelamanchili P, Nanda NC, Patel V, Fan P et al. Live/real time three-dimensional transthoracic echocardiographic assessment of tricuspid valve pathology: incremental value over the two-dimensional technique. *Echocardiography* 2007;24:541-52.
91. Quinones MA, Otto CM, Stoddard M, Waggoner A, Zoghbi WA. Doppler Quantification Task Force of the Nomenclature and Standards Committee of the American Society of Echocardiography. Recommendations for quantification of Doppler echocardiography: a report from the Doppler Quantification Task Force of the Nomenclature and Standards Committee of the American Society of Echocardiography. *J Am Soc Echocardiogr* 2002;15:167-84.
92. Hatle L. Noninvasive assessment of valve lesions with Doppler ultrasound. *Herz* 1984;9:213-21.
93. Fawzy ME, Mercer EN, Dunn B, al-Amri M, Andaya W. Doppler echocardiography in the evaluation of tricuspid stenosis. *Eur Heart J* 1989;10: 985-90.
94. Karp K, Teien D, Eriksson P. Doppler echocardiographic assessment of the valve area in patients with atrioventricular valve stenosis by application of the continuity equation. *J Intern Med* 1989;225: 261-6.
95. Weyman AE, Hurwitz RA, Girod DA, Dillon JC, Feigenbaum H, Green D. Cross-sectional echocardiographic visualization of the stenotic pulmonary valve. *Circulation* 1977;56:769-74.
96. Weyman AE, Dillon JC, Feigenbaum H, Chang S. Echocardiographic differentiation of infundibular from valvular pulmonary stenosis. *Am J Cardiol* 1975;36:21-6.
97. Waller BF, Howard J, Fess S. Pathology of pulmonic valve stenosis and pure regurgitation. *Clin Cardiol* 1995;18:45-50.
98. Bandin MA, Vargas-Barron J, Keirns C, Romero-Cardenas A, Villegas M, Buendia A. Echocardiographic diagnosis of rheumatic cardiopathy affecting all four cardiac valves. *Am Heart J* 1990;120:1004-7.
99. Fox R, Panidis IP, Kotler MN, Mintz GS, Ross J. Detection by Doppler echocardiography of acquired pulmonic stenosis due to extrinsic tumor compression. *Am J Cardiol* 1984;53:1475-6.
100. Van Camp G, De Mey J, Daenen W, Budts W, Schoors D. Pulmonary stenosis caused by extrinsic compression of an aortic pseudoaneurysm of a composite aortic graft. *J Am Soc Echocardiogr* 1999;12:997-1000.
101. Lima CO, Sahn DJ, Valdes-Cruz LM, Goldberg SJ, Barron JV, Allen HD et al. Noninvasive prediction of transvalvular pressure gradient in patients with pulmonary stenosis by quantitative two-dimensional echocardiographic Doppler studies. *Circulation* 1983;67:866-71.
102. Aldousany AW, DiSessa TG, Dubois R, Alpert BS, Willey ES, Birnbaum SE. Doppler estimation of pressure gradient in pulmonary stenosis: maximal instantaneous vs peak-to-peak, vs mean catheter gradient. *Pediatr Cardiol* 1989;10:145-9.
103. Frantz EG, Silverman NH. Doppler ultrasound evaluation of valvar pulmonary stenosis from multiple transducer positions in children requiring pulmonary valvuloplasty. *Am J Cardiol* 1988;61:844-9.
104. Johnson GL, Kwan OL, Handshoe S, Noonan JA, DeMaria AN. Accuracy of combined two-dimensional echocardiography and continuous wave Doppler recordings in the estimation of pressure gradient in right ventricular outlet obstruction. *J Am Coll Cardiol* 1984;3:1013-8.
105. Silvilairat S, Cabalka AK, Cetta F, Hagler DJ, O'Leary PW. Echocardiographic assessment of isolated pulmonary valve stenosis: which outpatient Doppler gradient has the most clinical validity? *J Am Soc Echocardiogr* 2005;18:1137-42.
106. Chen CR, Cheng TO, Huang T, Zhou YL, Chen JY, Huang YG et al. Percutaneous balloon valvuloplasty for pulmonic stenosis in adolescents and adults. *N Engl J Med* 1996;335:21-5.
107. Foale R, Nihoyannopoulos P, McKenna W, Kleinebenne A, Nadazdin A, Rowland E et al. Echocardiographic measurement of the normal adult right ventricle. *Br Heart J* 1986;56:33-44.
108. Matsukubo H, Matsuura T, Endo N, Asayama J, Watanabe T. Echocardiographic measurement of right ventricular wall thickness. A new application of subxiphoid echocardiography. *Circulation* 1977;56: 278-84.
109. Lang RM, Bierig M, Devereux RB, Flachskampf FA, Foster E, Pellikka PA et al. Recommendations for chamber quantification. *Eur J Echocardiogr* 2006;7:79-108.