

# Basic Perioperative Transesophageal Echocardiography Examination: A Consensus Statement of the American Society of Echocardiography and the Society of Cardiovascular Anesthesiologists

Scott T. Reeves, MD, FASE, Alan C. Finley, MD, Nikolaos J. Skubas, MD, FASE, Madhav Swaminathan, MD, FASE, William S. Whitley, MD, Kathryn E. Glas, MD, FASE, Rebecca T. Hahn, MD, FASE, Jack S. Shanewise, MD, FASE, Mark S. Adams, BS, RDCS, FASE, and Stanton K. Shernan, MD, FASE, for the Council on Perioperative Echocardiography of the American Society of Echocardiography and the Society of Cardiovascular Anesthesiologists, *Charleston, South Carolina; New York, New York; Durham, North Carolina; Atlanta, Georgia; Boston, Massachusetts*

(J Am Soc Echocardiogr 2013;26:443-56.)

**Keywords:** Transesophageal echocardiography, Basic certification

## TABLE OF CONTENTS

Introduction	443
History	444
Medical Knowledge	444

From the Medical University of South Carolina (S.T.R., A.C.F.); Weill-Cornell Medical College, New York, New York (N.J.S.); Duke University, Durham, North Carolina (M.S.); Brigham's and Women's Hospital, Harvard Medical School, Boston, Massachusetts (S.K.S.); Emory University, Atlanta, Georgia (W.S.W., K.E.G.); Columbia University College of Physicians and Surgeons, New York, New York (R.T.H., J.S.S.); and Massachusetts General Hospital, Boston, Massachusetts (M.S.A.).

The following authors reported relationships with one or more commercial interests: Scott T. Reeves, MD, FASE, edited and receives royalties for *A Practical Approach to Transesophageal Echocardiography* and *The Practice of Perioperative Transesophageal Echocardiography: Essential Cases* (Wolters Kluwer Health). Kathryn E. Glas, MD, FASE, edited and receives royalties for *The Practice of Perioperative Transesophageal Echocardiography: Essential Cases* (Wolters Kluwer Health). Stanton K. Shernan, MD, FASE, has served as a lecturer for Philips Healthcare, Inc., and is an editor for [e-Echocardiography.com](http://e-Echocardiography.com). All other authors reported no actual or potential conflicts of interest in relation to this document.

Members of the Councils on Perioperative Echocardiography are listed in the [Appendix](#).

### Attention ASE Members:

The American Society of Echocardiography (ASE) has gone green! Visit [www.aseuniversity.org](http://www.aseuniversity.org) to earn free continuing medical education credit through an online activity related to this article. Certificates are available for immediate access upon successful completion of the activity. Nonmembers will need to join the ASE to access this great member benefit!

Training	445
Basic Perioperative Transesophageal Examination	445
ME Four-Chamber View	446
ME Two-Chamber View	447
ME Long-Axis (LAX) View	447
ME Ascending Aortic LAX View	447
ME Ascending Aortic SAX View	447
ME AV SAX View	447
ME RV Inflow-Outflow View	447
ME Bicaval View	448
TG Midpapillary SAX View	449
Descending Aortic SAX and LAX Views	450
Indications	450
Global and Regional LV Function	451
RV Function	451
Hypovolemia	452
Basic Valvular Lesions	452
Pulmonary Embolism (PE)	452
Neurosurgery: Air Embolism	452
Pericardial Effusion and Thoracic Trauma	453
Simple Congenital Heart Disease in Adults	453
Maintenance of Competence and Quality Assurance	453
Conclusions	454
Notice and Disclaimer	454
Appendix	454
Members of the Council on Perioperative Echocardiography	454
References	454

Reprint requests: American Society of Echocardiography, 2100 Gateway Centre Boulevard, Suite 310, Morrisville, NC 27560 (E-mail: [ase@asecho.org](mailto:ase@asecho.org)).

0894-7317/\$36.00

Copyright 2013 by the American Society of Echocardiography.

<http://dx.doi.org/10.1016/j.echo.2013.02.015>

## INTRODUCTION

This consensus statement by the American Society of Echocardiography (ASE) and the Society of Cardiovascular Anesthesiologists (SCA) describes the significant role of a basic

**Abbreviations****ASA** = American Society of Anesthesiologists**ASD** = Atrial septal defect**ASE** = American Society of Echocardiography**AV** = Aortic valve**IAS** = Interatrial septum**LAD** = Left anterior descending**LAX** = Long-axis**LCX** = Left circumflex**LV** = Left ventricular**LVOT** = Left ventricular outflow tract**ME** = Midesophageal**MV** = Mitral valve**NBE** = National Board of Echocardiography**PA** = Pulmonary artery**PTE** = Perioperative transesophageal**PTEeXAM** = Perioperative TEE Examination**PV** = Pulmonic valve**RCA** = Right coronary artery**RV** = Right ventricular**RVOT** = Right ventricular outflow tract**SCA** = Society of Cardiovascular Anesthesiologists**TEE** = Transesophageal echocardiography**TG** = Transgastric**TV** = Tricuspid valve**VAE** = Venous air embolism

perioperative transesophageal (PTE) cardiac examination in the care and treatment of an unstable surgical patient. The use of a noncomprehensive basic PTE examination to delineate the cause of hemodynamic instability was originally proposed for the emergency room and neonatal intensive care unit settings and is meant to be complementary to comprehensive echocardiography.<sup>1,2</sup> However, the principal goal of a basic PTE examination is intraoperative monitoring.<sup>3</sup> Whereas this may encompass a broad range of anatomic imaging, the intent of noninvasive monitoring should focus on cardiac causes of hemodynamic or ventilatory instability, including ventricular size and function, valvular anatomy and function, volume status, pericardial abnormalities and complications from invasive procedures, as well as the clinical impact or etiology of pulmonary dysfunction. The basic PTE examination is **not** designed to prepare practitioners to use the full diagnostic potential of transesophageal echocardiography (TEE). Therefore, a basic PTE practitioner should be prepared to request consultation with an advanced PTE practitioner on issues outside the scope of practice as defined within these guidelines. Echocardiographic assessments that influence the surgical plan are specifically excluded from this consensus statement, because their acquisition requires an advanced PTE skill set.

The purposes of the current document are

1. to review concisely the history of basic PTE certification,
2. to define the prerequisite medical knowledge,
3. to define the necessary training requirements,
4. to recommend an abbreviated basic PTE examination sequence,
5. to summarize the appropriate indications of basic PTE examination, and
6. to define maintenance of competence and quality assurance.

**HISTORY**

TEE was introduced to cardiac operating rooms in the early 1980s.<sup>3</sup> Many guidelines have been written that further expand on its utility to facilitate surgical decision making.<sup>4-8</sup> The idea of distinguishing basic PTE skills was incorporated into the American Society of

Anesthesiologists (ASA) and SCA practice guidelines for perioperative TEE, published in 1996.<sup>4</sup> In 2002, training guidelines in perioperative echocardiography that include specific case number recommendations for training in basic and advanced PTE echocardiography were endorsed by the ASE and the SCA.<sup>5</sup> The evolution of the perioperative echocardiographic guidelines is summarized in Table 1.

The National Board of Echocardiography (NBE) was created in 1998 as a collaborative effort between the ASE and the SCA. The mission of the NBE is "to improve the quality of cardiovascular patient care by developing and administering examinations leading to certification of licensed physicians with special knowledge and expertise in echocardiography," which is accomplished by

1. overseeing the development and administration of the Adult Special Competency in Echocardiography Examination, the Advanced Perioperative TEE Examination (PTEeXAM), and the Basic PTEeXAM;
2. recognizing physicians who successfully complete the examinations as *testamurs*; and
3. certifying physicians who have fulfilled training and/or experience requirements in echocardiography as *diplomates* of the NBE.

In 2006, the ASA House of Delegates approved the development and implementation of a program focused on basic echocardiography education. In 2009, a memorandum of understanding between the NBE and the ASA established a strategic partnership to mutually promote an examination and certification process in basic PTE echocardiography. Specifically, the basic PTE scope of practice was defined as the **limited application** of a basic PTE examination to "non-diagnostic monitoring within the customary practice of anesthesiology. Because the goal of, and training in, Basic PTE echocardiography is focused on intraoperative monitoring rather than specific diagnosis, except in emergent situations, diagnoses requiring intraoperative cardiac surgical intervention or post-operative medical/surgical management must be confirmed by an individual with advanced skills in TEE or by an independent diagnostic technique." A comprehensive and quantitative examination is thus not in the scope of the basic PTE examination, but those performing basic PTE echocardiography must be able to recognize specific diagnoses that may require advanced imaging skills and competence.

NBE criteria for certification in basic PTE echocardiography include

1. possession of a current medical license,
2. current board certification in anesthesiology,
3. completion of one of the perioperative TEE training pathways (Table 2), and
4. passing the Basic PTEeXAM or Advanced PTEeXAM.

**MEDICAL KNOWLEDGE**

PTE echocardiography is an invasive medical procedure that carries rare but potentially life threatening complications and therefore must be performed only by qualified physicians. The application of basic PTE echocardiography can often dramatically influence a patient's intraoperative management. A thorough understanding of anatomy, physiology, and the surgical procedure is critical to appropriate application. Because of the risks, technical complexity, and potential impact of TEE on perioperative management, the basic PTE echocardiographer must be a *licensed physician*. Previous guidelines have addressed the cognitive knowledge and technical skills necessary for the successful use of PTE and are summarized in Table 3.<sup>4-7</sup> The NBE's Basic PTEeXAM knowledge base content outline is described in Table 4.

**Table 1** Evolution of perioperative echocardiography guidelines

Year	Citation	Society	Title	Purpose	Comments
1996	Anesthesiology 1996;84:986-1006	ASA/SCA	Practice Guidelines for Perioperative Transesophageal Echocardiography	Distinguish basic from advanced PTE skills	Cognitive and technical skills for basic and advanced PTE echocardiography are described; monitoring aspect of basic TEE is described; full diagnostic potential of advanced PTE echocardiography
1999	Anesth Analg 1999;89:870-884; J Am Soc Echocardiogr 1999;12:884-900	ASE/SCA	ASE/SCA Guidelines for Performing a Comprehensive Intraoperative Multiplane Transesophageal Echocardiography Examination	Describes 20 views making up a comprehensive transesophageal echocardiographic examination	
2002	Anesth Analg 2002;94:1384-1388	ASE/SCA	American Society of Echocardiography and Society of Cardiovascular Anesthesiologists Task Force Guidelines for Training in Perioperative Echocardiography	Training objectives and number of required transesophageal echocardiographic examinations are set	
2006	J Am Soc Echocardiogr 2006;19:1303-1313	ASE/SCA	American Society of Echocardiography/ Society of Cardiovascular Anesthesiologists Recommendations and Guidelines for Continuous Quality Improvement in Perioperative Echocardiography	Establish recommendations and guidelines for a continuous quality improvement program specific to the perioperative environment	
2010	Anesthesiology 2010;112:1084 -1096	ASA/SCA	Practice Guidelines for Perioperative Transesophageal Echocardiography	Update of 1996 document	

## TRAINING

Cahalan *et al.*<sup>5</sup> provided guidelines for components of basic and advanced training in 2002. The NBE relied on this document as a guideline for basic PTE certification. The components of basic PTE training include independent clinical experience, supervision, and continuing education requirements (Table 2).

## BASIC PERIOPERATIVE TRANSESOPHAGEAL EXAMINATION

PTE is relatively safe and has been associated with mortality of <1 per 10,000 patients and morbidity of 2 to 5 per 1,000 patients.<sup>9-15</sup> Probe manipulation, including positioning, turning, rotation, and imaging planes, has previously been extensively described in the ASE comprehensive document.<sup>6</sup>

Prior guidelines developed by the ASE and the SCA have described the technical skills for acquiring 20 views in the performance of a comprehensive intraoperative multiplane transesophageal echocardiographic examination.<sup>6</sup> The current writing committee believes that although a basic PTE echocardiographer should be familiar with

the technical skills needed to acquire these 20 views, it is nonetheless a realistic expectation that a **basic** PTE examination focus on encompassing the 11 most relevant views, which can provide anesthesiologists with the necessary information to use basic PTE echocardiography as a tool for diagnosing the general etiology of hemodynamic instability in surgical patients. If complex pathology is anticipated or suspected (e.g., valvular abnormality or aortic dissection), appropriate consultation with an advanced echocardiographer is indicated. Figure 1 demonstrates the ASE and SCA comprehensive 11-view basic PTE examination. The basic PTE examination starts in the midesophageal (ME) four-chamber view. It is the expectation of this writing group that a basic PTE examination can be performed using three primary positions within the gastrointestinal tract (Figure 2): the ME level, the transgastric (TG) level, and the upper esophageal level. This writing group also recognizes that current advances in technology allow simultaneous multiplane imaging of real-time images, which may reduce the acquisition time for the basic PTE examination views.<sup>16</sup> *It is the expectation of the writing group that a complete basic PTE examination be performed on each patient as a standard examination. Once completed and stored, a more focused examination can be used for monitoring and to track changes in therapy. As noted in prior guidelines, this writing group also recognizes that individual patient characteristics, anatomic*

**Table 2** The NBE's Basic PTE training pathways

	Clinical experience in basic PTE echocardiography	Supervision of training	Continuing medical education
Supervised training pathway	≥150 basic PTE echocardiographic examinations studied under supervision	≥50 of the 150 basic intraoperative transesophageal echocardiographic examinations must be performed and interpreted under supervision throughout the procedure	No requirement
Practice experience pathway*	≥150 basic intraoperative transesophageal echocardiographic examinations performed and interpreted within 4 y of application, with ≤25 examinations in any 1 y	Supervision not required	≥40 American Medical Association Physician Recognition Award Category 1 Credits focused perioperative TEE and completed within the same period as the clinical experience

Adapted with permission from *Anesthesiology*.<sup>4</sup>

\*The practice experience pathway will not be available to those completing their anesthesiology residency training after June 30, 2016.

**Table 3** Recommended training objectives for basic PTE training**Cognitive skills**

1. Knowledge of the physical principles of echocardiographic image formation and blood velocity measurement
2. Knowledge of the operation of ultrasonographs, including all controls that affect the quality of data displayed
3. Knowledge of the equipment handling, infection control, and electrical safety associated with the techniques of perioperative echocardiography
4. Knowledge of the indications, contraindications, and potential complications of perioperative echocardiography
5. Knowledge of the appropriate alternative diagnostic techniques
6. Knowledge of the normal tomographic anatomy as revealed by perioperative echocardiographic techniques
7. Knowledge of commonly encountered blood flow velocity profiles as measured by Doppler echocardiography
8. Knowledge of the echocardiographic manifestations of native valvular lesions and dysfunction
9. Knowledge of the echocardiographic manifestations of cardiac masses, thrombi, cardiomyopathies, pericardial effusions, and lesions of the great vessels
10. Knowledge of the echocardiographic presentations of myocardial ischemia and infarction
11. Knowledge of the echocardiographic presentations of normal and abnormal ventricular function
12. Knowledge of the echocardiographic presentations of air embolization

**Technical skills**

1. Ability to operate ultrasonographs, including the primary controls affecting the quality of the displayed data
2. Ability to insert a transesophageal echocardiographic probe safely in an anesthetized, tracheally intubated patient
3. Ability to perform a basic PTE echocardiographic examination and differentiate normal from markedly abnormal cardiac structures and function
4. Ability to recognize marked changes in segmental ventricular contraction indicative of myocardial ischemia or infarction
5. Ability to recognize marked changes in global ventricular filling and ejection
6. Ability to recognize air embolization
7. Ability to recognize gross valvular lesions and dysfunction
8. Ability to recognize large intracardiac masses and thrombi
9. Ability to detect large pericardial effusions
10. Ability to recognize common echocardiographic artifacts
11. Ability to communicate echocardiographic results effectively to health care professionals, the medical record, and patients
12. Ability to recognize complications of perioperative echocardiography

Adapted with permission from *Anesth Analg* 2002;94:1384-1388.

*variations, pathologic features, or time constraints imposed on performing the basic PTE examination may limit the ability to perform every aspect of the examination and, furthermore, that there may be other entirely acceptable approaches and views of an intraoperative examination, provided they obtain similar information in a safe manner.*<sup>6</sup>

**ME Four-Chamber View**

The ME four-chamber view is obtained by advancing the probe to a depth of approximately 30 to 35 cm until it is immediately posterior to the left atrium (Figure 3, Video 1 [available at [www.onlinejase.com](http://www.onlinejase.com)]). Turning the probe to the left (counterclockwise rotation of the probe) or to the right (clockwise rotation of the probe) is per-

formed to center the mitral valve (MV) and left ventricle in the sector display. The image depth is then adjusted to ensure viewing of the left ventricular (LV) apex. The multiplane angle should be rotated to approximately 10° to 20° until the aortic valve (AV) or LV outflow tract (LVOT) is no longer in the display and the tricuspid annular dimension is maximized. Because the apex is at a slightly inferior plane to the left atrium, slight retroflexion may be required to align the MV and LV apex. Required structures seen include the right atrium, interatrial septum (IAS), left atrium, MV, tricuspid valve (TV), left ventricle, right ventricle, and interventricular septum. This view will allow the identification of both the anterior and posterior leaflets of the MV, the TV septal leaflet adjacent to the interventricular septum, to the right of the



**Table 4** Basic PTE examination content outline

1. Patient safety considerations
2. Echocardiographic imaging: acquisition and optimization
3. Normal cardiac anatomy and imaging plane correlation
4. Global ventricular function
5. Regional ventricular systolic function and recognition of pathology
6. Basic recognition of cardiac valve abnormalities
7. Identification of intracardiac masses in noncardiac surgery
8. Basic perioperative hemodynamic assessment
9. Related diagnostic modalities
10. Basic recognition of congenital heart disease in adults
11. Surface ultrasound for vascular access

Source: National Board of Echocardiography.<sup>80</sup>

sector display, and the TV posterior leaflet adjacent to the RV free wall, to the left of the display. Diagnostic information regarding chamber volume and function, MV and TV function, and assessment of global LV and right ventricular (RV) systolic function and of regional LV inferoseptal and anterolateral walls can be determined. In the ME four-chamber view (Figure 4), the basal anterolateral, mid anterolateral, and apical lateral wall segments are perfused by the left anterior descending (LAD) or left circumflex (LCX) coronary artery, the apical septum and the apical cap by the LAD coronary artery, the mid inferoseptum by the right coronary artery (RCA) or LAD coronary artery, and the basal inferoseptum by the RCA.<sup>17</sup> A color flow Doppler sector with the Nyquist limit set to 50 to 60 cm/sec should be placed over both the MV and TV to aid in the identification of valvular pathology (regurgitation and/or stenosis), as well as to the IAS to identify shunt flow.

### ME Two-Chamber View

From the ME four-chamber view, rotating the multiplane angle forward to between 80° and 100° until the right ventricle disappears from the image will develop the ME two-chamber view (Figure 5, Video 2 [available at [www.onlinejase.com](http://www.onlinejase.com)]). Structures seen in the image include the left atrium, MV, left ventricle, and left atrial appendage. Diagnostic information obtained from this view includes global and regional LV function, MV function, and regional assessment of the LV anterior and inferior walls. The basal inferior and mid inferior wall segments are perfused by the RCA, whereas the apical inferior, apical cap, apical anterior, mid anterior, and basal anterior wall segments are perfused by the LAD coronary artery (Figure 4). A color flow Doppler sector with the Nyquist limit at 50 to 60 cm/sec should be applied over the MV to aid in the identification of valvular pathology (regurgitation and/or stenosis). The coronary sinus is seen in short axis (SAX), as a round structure immediately superior to the basal inferior LV segment.

### ME Long-Axis (LAX) View

From the ME two-chamber view, rotating the multiplane angle forward to between 120° and 160° until the LVOT and AV come into the display develops the ME LAX view (Figure 6, Video 3 [available at [www.onlinejase.com](http://www.onlinejase.com)]). Visualized structures include the left atrium, MV, left ventricle, LVOT, AV, and proximal ascending aorta. This view offers diagnostic information regarding chamber volume and function, MV and AV function, LVOT pathology, and regional assessment of the left ventricle. The basal inferolateral and mid inferolateral wall segments are perfused by the RCA or LCX coronary artery, whereas the apical lateral, apical cap, apical anterior, mid antero-septum, and basal antero-septum wall segments are perfused by the LAD coronary

artery (Figure 4). Color flow Doppler can be applied to the MV, LVOT, and AV to aid in the identification of valvular pathology (regurgitation and/or stenosis).

### ME Ascending Aortic LAX View

Withdrawing the probe from the ME LAX view allows imaging of the LAX of the ascending aorta (Figure 7, Video 4 [available at [www.onlinejase.com](http://www.onlinejase.com)]). The right pulmonary artery (PA) is adjacent to the esophagus and posterior to the ascending aorta. When the image is centered on this structure, counterclockwise rotation results in LAX imaging of the main PA and the pulmonic valve (PV). Because the LAX of the PA is parallel to the insonation beam, this is an optimal view for pulsed-wave or continuous-wave Doppler of the RV outflow tract (RVOT) or PV. Proximal pulmonary emboli can sometimes be seen from this view.

### ME Ascending Aortic SAX View

From the image of the main PA, rotating the multiplane angle back to 20° to 40° images the bifurcation of the PA, the SAX view of the ascending aorta, and the SAX view of the superior vena cava (ME ascending aortic SAX; Figure 8, Video 5 [available at [www.onlinejase.com](http://www.onlinejase.com)]). Structures seen in this view include the proximal ascending aorta, superior vena cava, PV, and proximal (main) PA. Proximal pulmonary emboli can sometimes be seen from this view.

### ME AV SAX View

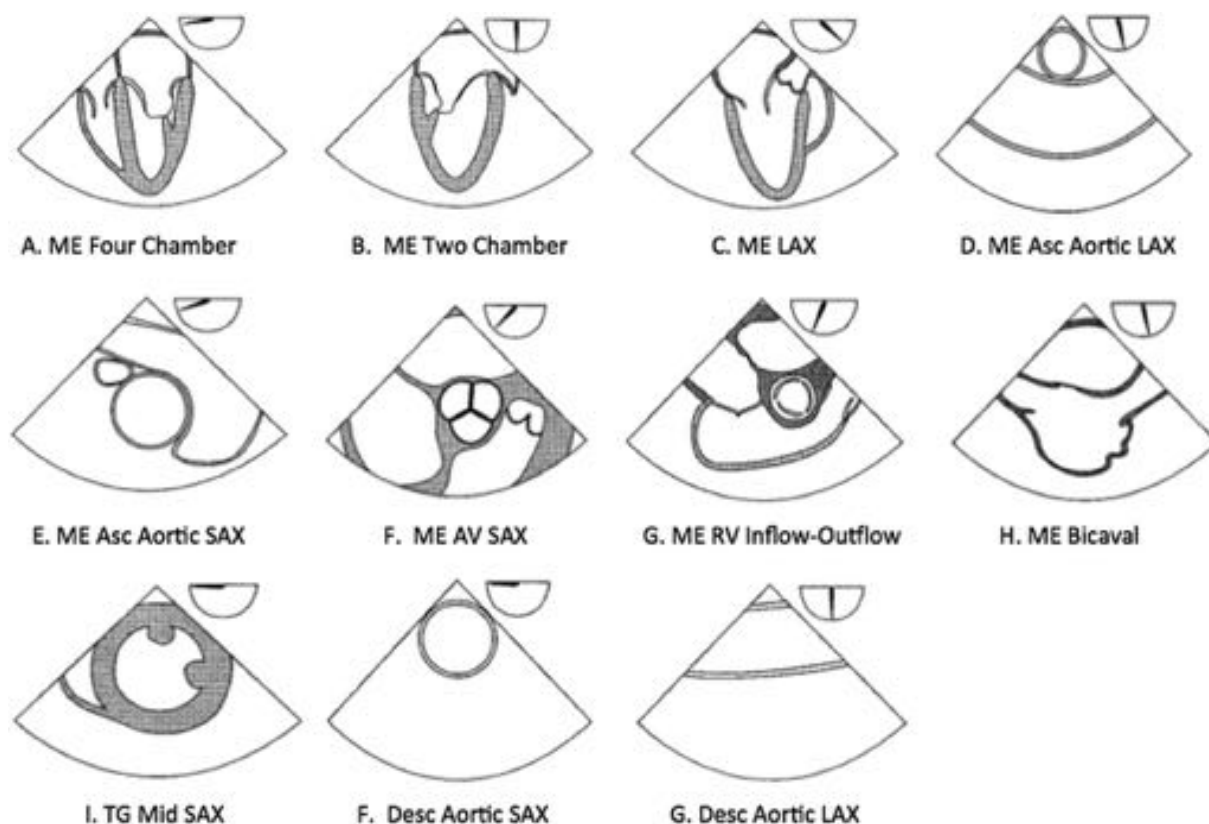
Advancing the probe from the ME ascending aortic SAX view results in SAX imaging of the AV (ME AV SAX; Figure 9, Video 6 [available at [www.onlinejase.com](http://www.onlinejase.com)]). The AV cusps should be clearly identified. For a trileaflet valve, the left coronary cusp should be posterior and on the right side of the image. The noncoronary cusp is adjacent to the IAS. The right coronary cusp is anterior and adjacent to the RVOT. Color flow Doppler can be applied over the AV to aid in identifying aortic regurgitation.

### ME RV Inflow-Outflow View

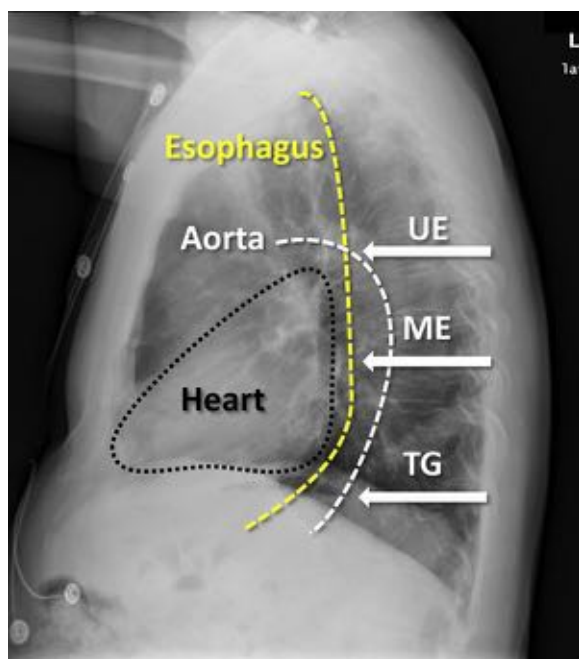
From the ME ascending aortic SAX view, the probe is advanced and turned clockwise to center the TV in the view, while the multiplane angle is rotated forward to between 60° and 90° until the RVOT and the PV appear in the display, indicating the ME RV inflow-outflow view (Figure 10, Video 7 [available at [www.onlinejase.com](http://www.onlinejase.com)]). Structures seen in this view include the left atrium, right atrium, TV, right ventricle, PV, and proximal (main) PA. The RV free wall is visualized on the left of the display, while the RVOT is on the right. This view offers diagnostic information regarding RV volume and function and TV and PV function. Color flow Doppler can be applied to the TV and PV to aid in the identification of valvular pathology (insufficiency or stenosis). If a parallel Doppler beam alignment with the tricuspid regurgitation color jet is possible, the RV systolic pressure can be estimated using the modified Bernoulli equation:

$$\text{RV systolic pressure} = 4 \times (\text{tricuspid regurgitation peak velocity jet})^2 + \text{central venous pressure},$$

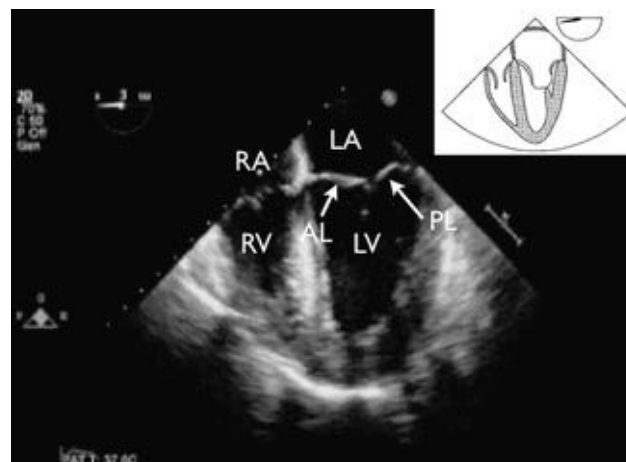
where central venous pressure is measured using a central venous line or is estimated. RV systolic pressure equals PA systolic pressure if there is no pulmonary stenosis, which is easily excluded by TEE. If a parallel Doppler beam alignment is not possible, significant underestimation of the jet velocity will occur, resulting in underestimation of RV systolic pressure.



**Figure 1** Cross-sectional views of the 11 views of the ASE and SCA basic PTE examination. The approximate multiplane angle is indicated by the icon adjacent to each view. Asc, Ascending; Desc, descending; UE, upper esophageal.



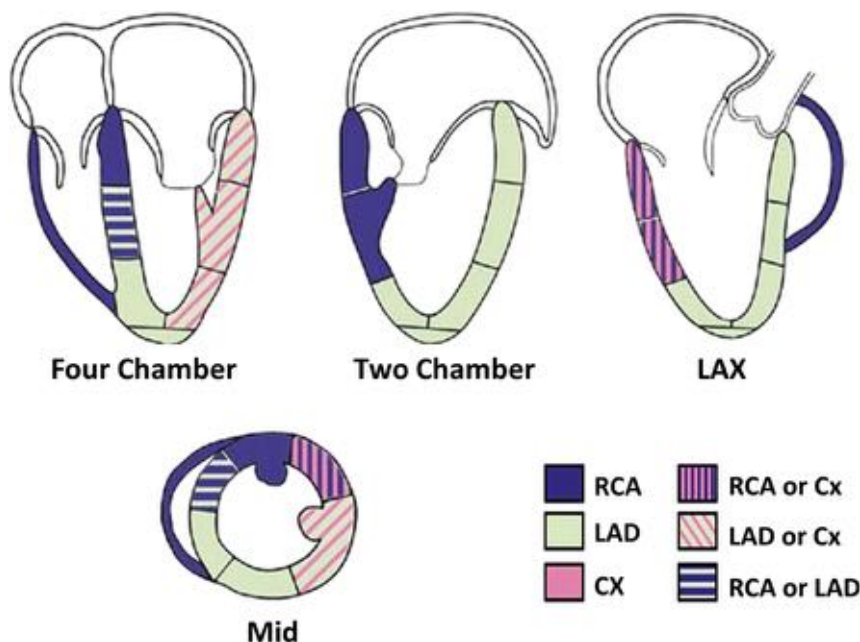
**Figure 2** Lateral chest x-ray depicting relative positions of the heart (black outline), aorta (white line), and esophagus (yellow line). Arrows indicate the upper esophageal (UE), ME, and TG positions of the transesophageal echocardiographic probe.



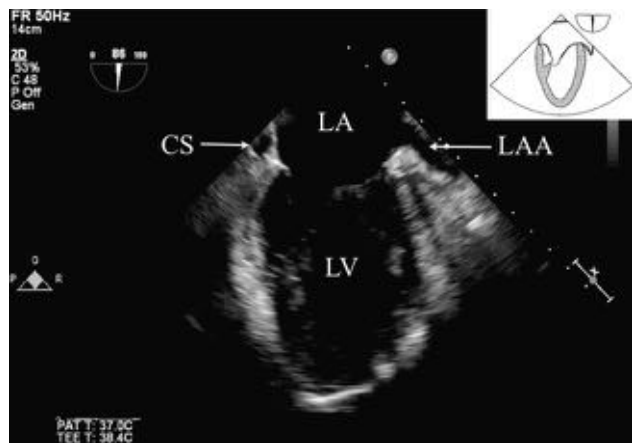
**Figure 3** ME four-chamber view. AL, Anterior leaflet of the MV; LA, left atrium; LV, left ventricle; PL, posterior leaflet of the MV; RA, right atrium; RV, right ventricle.

#### ME Bicaval View

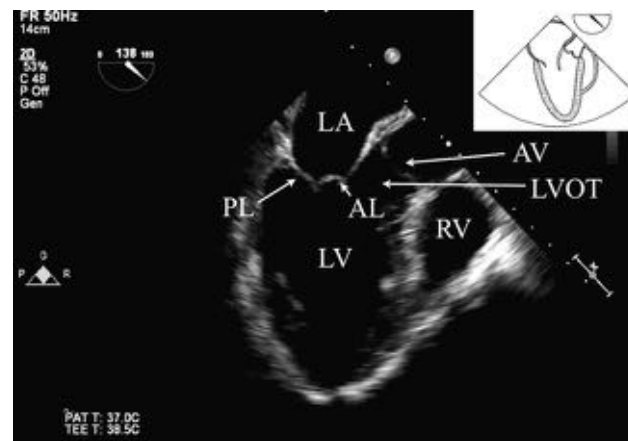From the ME RV inflow-outflow view, the multiplane angle is rotated forward to 90° to 110° and the probe is turned clockwise to the ME bicaval view (Figure 11, Video 8 [available at [www.onlinejase.com](http://www.onlinejase.com)]). From this view, catheters or pacing wires entering the right atrium from the superior vena cava are well imaged. Structures seen in the



**Figure 4** Typical distributions of the RCA, the LAD coronary artery, and the circumflex (CX) coronary artery from transesophageal views of the left ventricle. The arterial distribution varies among patients. Some segments have variable coronary perfusion. Modified with permission from Lang *et al.*<sup>17</sup>



**Figure 5** ME two-chamber view. CS, Coronary sinus; LA, left atrium; LAA, left atrial appendage; LV, left ventricle.



**Figure 6** ME LAX view. AL, Anterior leaflet of the MV; LA, left atrium; LV, left ventricle; PL, posterior leaflet of the MV; RV, right ventricle.

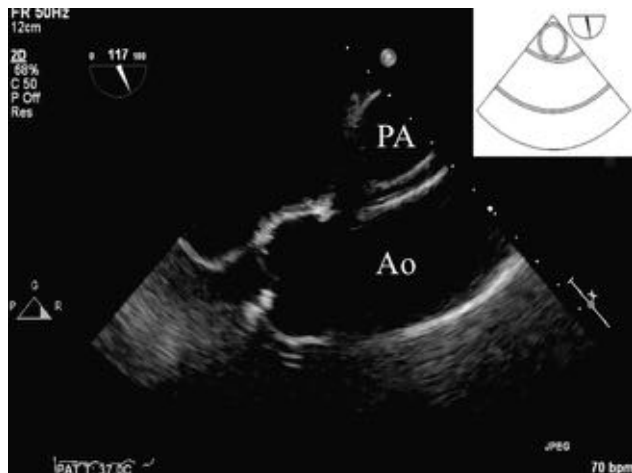
view include the left atrium, right atrium, right atrial appendage, and IAS. Motion of the IAS should be observed because atrial septal aneurysms are associated with interatrial shunts. Color Doppler of the IAS, including the use of a lower Nyquist limit setting, may be used to assess the presence of a low-velocity interatrial shunt. Agitated saline may also be injected after the administration of a Valsalva maneuver for further documentation of a right-to-left component.

#### TG Midpapillary SAX View

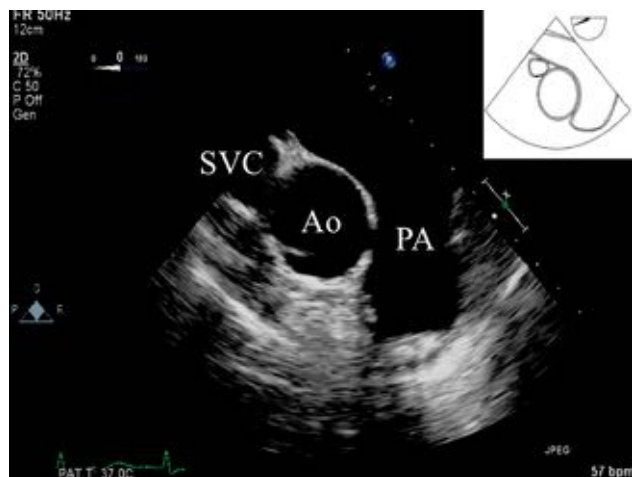From the ME four-chamber view (at 0°), the probe is advanced into the stomach and anteфлекed to come in contact with the gastric wall. The multiplane angle should remain at 0°. Proper positioning requires a two-step process. First, probe depth is manipulated until the posteromedial papillary muscle comes into view at the top of the im-

age display. Visualization of the MV leaflet chords indicates that the probe should be advanced, whereas not visualizing any papillary muscles indicates that the probe is too deep and should be withdrawn. Once the posteromedial papillary muscle is in view, visualization of the anterolateral papillary muscle is optimized by varying the degree of anteфлекion. If MV leaflet chords are seen, anteфлекion should be decreased, whereas not visualizing any papillary muscles indicates that anteфлекion should be increased.

The TG midpapillary SAX view provides significant diagnostic information and can be extremely helpful in hemodynamically unstable patients (Figure 12, Video 9 [available at [www.onlinejase.com](http://www.onlinejase.com)]). LV volume status, systolic function, and regional wall motion can be obtained in this view. This is the only view in which the myocardium supplied by the LAD coronary artery, LCX coronary artery, and RCA can be seen simultaneously (Figure 4). The inferior wall segment is perfused by the RCA.



**Figure 7** ME ascending aortic LAX view. Ao, Aorta.

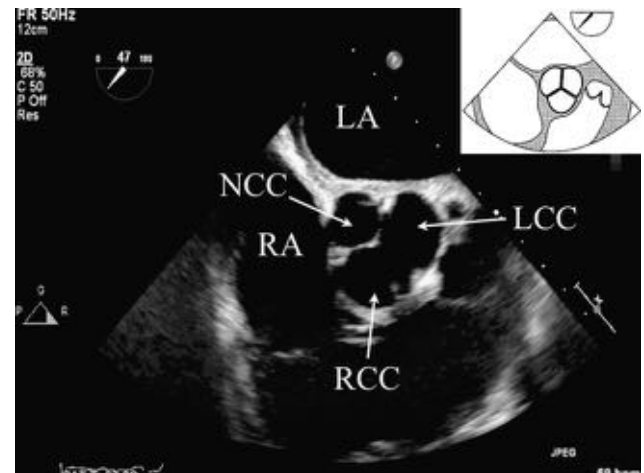


**Figure 8** ME ascending aortic SAX view. Ao, Aorta; SVC, superior vena cava.

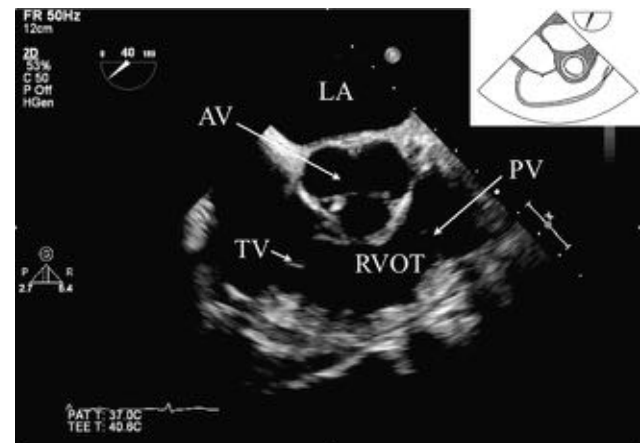
The inferoseptum is perfused by either the RCA or the LAD coronary artery. The anterosseptum and anterior wall segments are perfused by the LAD coronary artery. The anterolateral wall segment is perfused by either the LAD coronary artery or the LCX coronary artery. Finally, the inferolateral wall segment is perfused by either the RCA or the LCX coronary artery.<sup>17</sup> The development of a new wall motion abnormality in one of these regions could indicate myocardial ischemia. A pericardial effusion can be seen as a distinctive echo-free space separating the epicardium from the pericardium. The ability to simultaneously monitor and acquire all of this information makes the TG midpapillary SAX view very popular for intraoperative monitoring.

### Descending Aortic SAX and LAX Views

Imaging of the descending thoracic aorta during a basic PTE examination is easily performed, because the aorta is immediately adjacent to the esophagus in the mediastinum. The descending aorta is visualized by turning the probe to the left from the ME four-chamber view until the descending thoracic aorta comes into the display. The SAX view of the aorta is obtained at a multiplane angle of 0° (Figure 13, Video 10 [available at [www.onlinejase.com](http://www.onlinejase.com)]), while the LAX view is obtained at a multiplane angle of approximately 90° (Figure 14, Video



**Figure 9** ME AV SAX view. LA, Left atrium; LCC, left coronary cusp; NCC, noncoronary cusp; RA, right atrium; RCC, right coronary cusp.



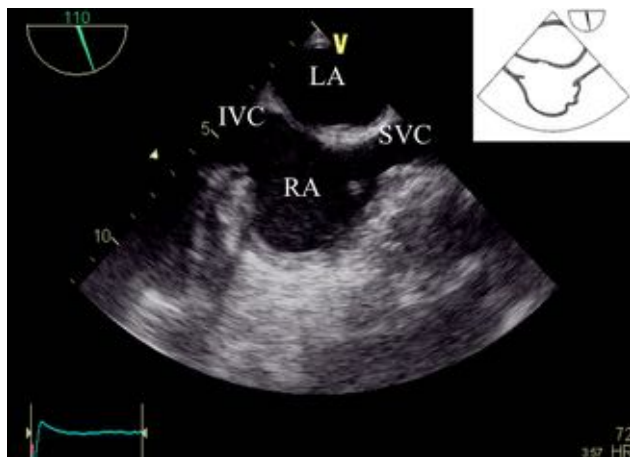
**Figure 10** ME RV inflow-outflow view. LA, Left atrium.

11 [available at [www.onlinejase.com](http://www.onlinejase.com)]). Image depth should be decreased to enlarge the size of the aorta and the focus set to be in the near field. Finally, gain should be increased in the near field to optimize imaging. While keeping the aorta in the center of the image, the probe can be advanced and withdrawn to image the entire descending aorta. Because there are no internal anatomic landmarks in the descending aorta, describing the location of pathology may be difficult. One approach to this problem is to identify the location in terms of distance from the left subclavian artery and the location in the vessel wall relative to the esophagus. For follow-up examinations, the distance of the probe from the incisors should be reported. This view offers diagnostic information about aortic pathology, including aortic diameter, aortic atherosclerosis, and aortic dissection. Additionally, if left pleural fluid is present, this view offers visualization of the fluid in the far field. A right pleural effusion may be imaged by turning the probe further clockwise to image the right chest.

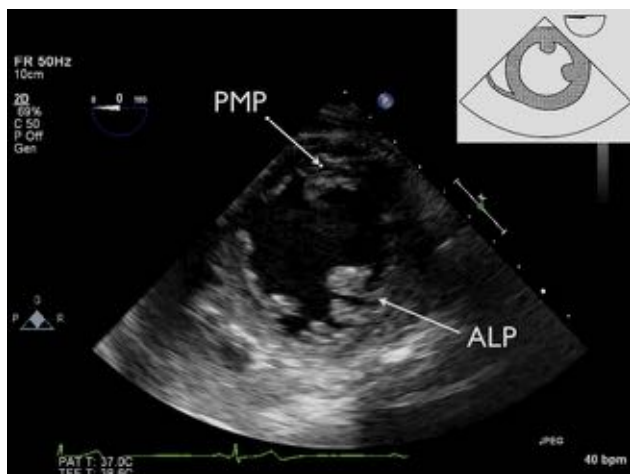
### INDICATIONS

The ASA practice guidelines recommend “appropriateness” criteria for performing basic and advanced PTE echocardiography in the





**Figure 11** ME bicaval view. IVC, Inferior vena cava; LA, left atrium; SVC, superior vena cava; RA, right atrium.

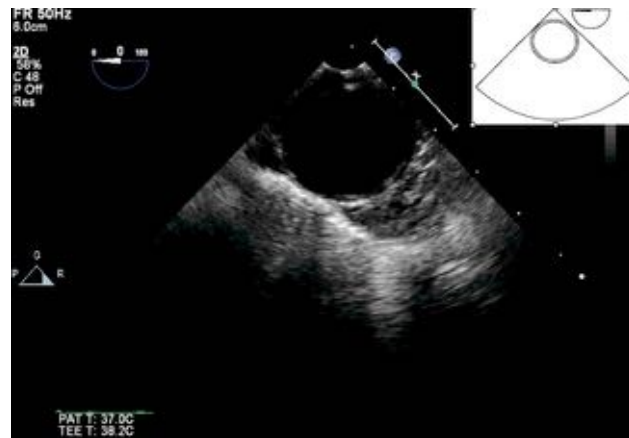


**Figure 12** TG midpapillary SAX view. ALP, Anterior lateral papillary muscle; PMP, posterior medial papillary muscle.

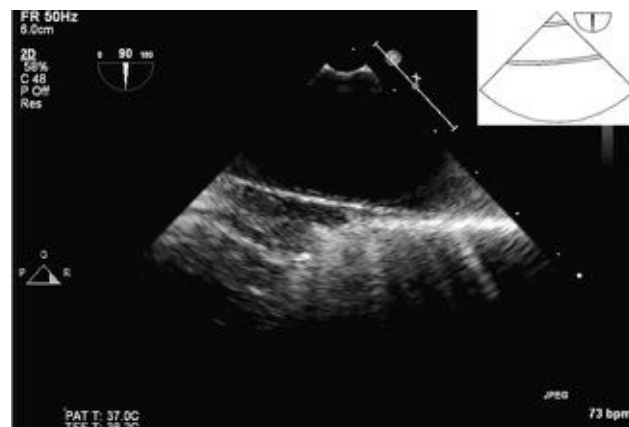context of the condition of the patient, the risks of the procedure, and the specific circumstances. These same ASA practice guidelines recommend basic PTE echocardiography when the nature of the planned surgery or the patient's known or suspected cardiovascular pathology might result in severe hemodynamic, pulmonary, or neurologic compromise. In addition, when available, basic PTE echocardiography should be used when unexplained life-threatening circulatory instability persists despite corrective therapy.<sup>7,18-21</sup> The goals of a basic PTE examination in a patient with hemodynamic instability include early diagnosis of the etiology of hypotension despite the use of inotropic and vasoactive support and guidance of therapeutic interventions to treat the underlying cause. Failure to take early corrective action may lead to end-organ damage and perioperative mortality. Multiple reports in the literature support the use and delineate the impact of transesophageal echocardiographic guidance and intraoperative decision making. Incidental findings play a large role in this impact and can significantly influence the surgical procedure and outcome.<sup>9,22-35</sup>

### Global and Regional LV Function

Determination of global LV systolic function is one of the most common indications of a basic PTE examination. Several techniques for



**Figure 13** Descending aortic SAX view.



**Figure 14** Descending aortic LAX view.

acquiring quantitative measures of global LV systolic function have been well described and are beyond the scope of this document.<sup>17</sup> Nonetheless, most basic echocardiographers rely on qualitative, visual estimation of systolic function. This method of determination is far from precise but allows a basic echocardiographer to identify those patients who might benefit from inotropic therapies. Multiple publications support the use of TEE in patients with severe hemodynamic disturbances and unknown ventricular function.<sup>26,27,30</sup> Regional wall motion analysis using a 17-segment wall motion score described in the ASE guidelines<sup>17</sup> can be performed using the ME four-chamber, ME two-chamber, and ME LAX views. However, visualization of 6 midpapillary segments from the TG midpapillary SAX view may suffice and has been shown to have prognostic importance.<sup>36</sup>

The TG midpapillary SAX view provides significant diagnostic information pertaining to regional and global ventricular function in the hemodynamically unstable patient. *However, it is the recommendation of the writing committee that a physician trained in basic PTE echocardiography also use the ME four-chamber, ME two-chamber, and ME LAX views for a more comprehensive evaluation and for monitoring of global and regional LV function.*

### RV Function

Several techniques for acquiring quantitative measures of global RV systolic function have been well described.<sup>17</sup> Nonetheless, most basic echocardiographers rely on a qualitative, visual estimation of systolic

function. Evaluation of RV function should be routinely performed when assessing hypotensive patients. For example, patients undergoing liver transplantation are at increased risk for hypotension secondary to RV failure.<sup>37</sup> Patients presenting for liver transplantation with pulmonary hypertension have additional risk for RV dysfunction secondary to acute changes in pulmonary pressures associated with volume shifts and acid base disturbances during transplantation.<sup>38</sup> Use of basic PTE echocardiography in this population allows rapid determination of cardiac status and therapeutic advantages over invasive monitoring alone. Wax *et al.*<sup>39</sup> showed TEE to be safe and effective in the liver transplantation population despite the presence of esophageal disease and coagulopathies.

*It is the recommendation of the writing committee that a physician trained in basic PTE echocardiography evaluate the right ventricle in cases of refractory hypotension and that basic PTE monitoring be considered for patients at high risk for RV dysfunction, in particular those patients undergoing nonthoracic procedures in whom direct inspection of the right ventricle is not possible.*

### Hypovolemia

Hypovolemia is a common cause of hemodynamic instability in the perioperative period. The most common echocardiographic parameters used to diagnose hypovolemia are LV end-diastolic diameter and LV end-diastolic area obtained in the TG midpapillary SAX view. In an emergent setting, a transesophageal echocardiographic probe can be placed quickly and provides real-time assessment of LV cavity size. Acute blood loss causes changes in LV end-diastolic area, PA occlusion pressure, and LV end-diastolic wall stress, even in patients with LV wall motion abnormalities.<sup>40</sup> Compared with baseline imaging, measurements of LV end-diastolic area can be used as an indirect measurement of LV preload<sup>40,41</sup> and can be used to monitor response to fluid therapy.<sup>42</sup> Compared with the more invasive PA catheterization, TEE has been shown to provide a better index of LV preload in patients with normal LV function.<sup>43-45</sup> More advanced Doppler-derived data can also be obtained, but this is time-consuming, requires advanced training, and may have limited accuracy in anesthetized patients.<sup>42</sup> Relative changes between baseline status and the critical event, however, remain useful in detecting acute changes in LV preload.

The use of basic PTE echocardiography as a monitor includes both intermittent acquisition of images and ongoing live imaging, particularly related to the TG midpapillary SAX view. A certified echocardiographer (basic or advanced) must be involved in the evaluation of images and its use to effect changes in management, whether it be used to direct volume resuscitation or pressor administration. It is outside the scope of practice for other individuals participating in patient management to interpret the basic PTE images and direct therapy, but it is reasonable for these individuals to request interpretation and management guidance from anesthesiologist echocardiographers.

*It is the recommendation of the writing committee that a physician trained in basic PTE echocardiography use the TG midpapillary SAX view to monitor and guide a hypovolemic patient's response to fluid and blood component therapy.*

### Basic Valvular Lesions

Practitioners of basic PTE echocardiography need familiarity with basic valvular lesions. This includes knowledge of color flow Doppler assessment of valvular regurgitation for the AV, MV, TV, and PV. Although specific semiquantitative assessments do not have to be obtained, differentiation of mild from moderate versus severe degrees of

insufficiency should be possible with visual inspection of regurgitant jet area within the receiving chamber and vena contracta width. Caution should be used when assessing the severity of eccentric jets. The mechanism of any regurgitant jet may require consultation with a physician with advanced PTE capabilities. Rapid assessment of possible stenotic valvular lesions can be made by visualizing leaflet motion and using continuous-wave Doppler through the valve in any imaging plane in which blood flow is parallel to the interrogating continuous-wave Doppler beam.

Complete assessment of valvular regurgitant and stenotic lesions is outlined in multiple ASE guideline documents.<sup>46,47</sup> The assessment of prosthetic valve function should be performed by a physician with advanced PTE knowledge. *It is the recommendation of the writing committee that a physician trained in basic PTE echocardiography use the complete basic PTE examination to qualitatively delineate valvular regurgitation and/or stenosis. However, if the valve lesion is considered severe, or if comprehensive quantification is required to ultimately determine the need for intervention, a consultation with an advanced PTE echocardiographer is necessary to confirm the severity and etiology of the valve pathology.*

### Pulmonary Embolism (PE)

Both surgery and trauma pose an increased risk for PE. Thus, anesthesiologists may be responsible for both PE diagnosis and treatment. Although TEE is not the gold standard for PE diagnosis, it compares well with computed tomography when the PE is acute and central.<sup>48,49</sup> Moreover, TEE is often readily available to anesthesiologists, and its use does not interfere with ongoing surgery. The sensitivity of two-dimensional TEE to diagnose a PE by direct visualization of a thrombus in the PA is actually quite low,<sup>50</sup> but studies using TEE to diagnose hemodynamically significant PEs have shown far better diagnostic sensitivity.<sup>48,49,51</sup> Echocardiographic findings consistent with acute PE include signs of RV dysfunction (e.g., RV dilation, RV hypokinesis)<sup>52</sup> and atypical regional wall motion abnormalities of the RV free wall.<sup>53</sup>

*In the opinion of the writing committee, the echocardiographic diagnosis of a PE using direct evidence often requires advanced PTE skills. In addition, previously recommended cognitive and technical objectives for basic PTE training have not included PE.<sup>4</sup> However, it is the recommendation of the writing committee that a physician trained in basic PTE echocardiography at least be able to use the ME four-chamber, ME ascending aortic SAX, and ME RV inflow-outflow views to identify indirect echocardiographic findings consistent with a PE, such as the presence of thrombus and/or signs of RV dysfunction, before the initiation of treatment.*

### Neurosurgery: Air Embolism

Venous air embolism (VAE) is a common occurrence during craniotomies in the sitting position and has an incidence as high as 76%.<sup>54</sup> Although the vast majority of VAEs are small with little clinical significance, the sequelae of massive VAE and paradoxical embolism across a patent foramen ovale can be catastrophic. Thus, early detection and treatment are necessary. Basic PTE echocardiography offers the advantage of providing both real-time data and a visual quantification of a VAE. TEE is a more sensitive method for the detection of VAE than precordial Doppler. In fact, it is potentially too sensitive, in that TEE can detect hemodynamically insignificant microbubbles.<sup>55</sup> Nevertheless, detection of these microbubbles may alert the clinician to an insignificant problem that can easily be addressed before it becomes significant. Last, basic PTE echocardiography allows the

detection of right-to-left shunts. Diagnosis of a shunt may influence the operative team to avoid the sitting position in this patient population, because these patients are prone to paradoxical embolisms.<sup>54,56-58</sup>

*Previously recommended training objectives for basic PTE training included the requirement for knowledge of the echocardiographic presentations of air embolization.<sup>4</sup> It is the recommendation of the writing committee that a physician trained in basic PTE echocardiography use a complete basic PTE examination to identify patients at risk for right-to-left shunts and be able to detect the early entrainment of intracardiac air.*

### Pericardial Effusion and Thoracic Trauma

Echocardiography plays an integral part in the evaluation of trauma involving the thoracic cavity. In trauma, rapid diagnosis and intervention are crucial to optimizing patient outcomes. The value of ultrasonography has long been recognized in the trauma literature,<sup>26,59-61</sup> as it is now part of the Focused Assessment With Sonography in Trauma examination.<sup>62</sup> Similarly, TEE offers a mobile diagnostic tool that provides a rapid, accurate diagnosis of pericardial effusions, traumatic aortic injuries, and cardiac contusions.<sup>26</sup> Both physical trauma (blunt or penetrating thoracic trauma) and iatrogenic trauma (during invasive procedures) can result in the accumulation of a pericardial effusion. If the effusion accumulates rapidly, hemodynamic instability may ensue, and TEE can facilitate treatment with pericardiocentesis. Many publications support the use of TEE for traumatic aortic injury given the safety, portability, and high diagnostic accuracy of this modality.<sup>62-69</sup> Nonetheless, it is important to keep in mind that visualization of the distal ascending aorta and aortic arch are quite limited via TEE. Diagnosis of cardiac contusions may also be difficult and limited in that there is no one diagnostic test for this condition. When used in conjunction with transthoracic echocardiography, serial electrocardiography, and serial myocardial enzyme assessment, TEE provides valuable diagnostic information.<sup>60,70-76</sup> However, caution should be used with TEE probe placement and manipulation because of a potential coexisting esophageal or cervical spine injury.

*Previously recommended training objectives for basic PTE training included the requirement for knowledge of the echocardiographic manifestations of pericardial effusions and lesions of the great vessels as appropriate cognitive skills.<sup>4</sup> Thus, it is the recommendation of the writing committee that a physician trained in basic PTE echocardiography use a complete basic PTE examination to demonstrate signs consistent with a pericardial effusion, aortic dissection, or cardiac contusion. However, once obtained, except in emergency situations, a consult with an advanced PTE echocardiographer is necessary to confirm the diagnosis and initiate appropriate surgical or medical therapy.*

### Simple Congenital Heart Disease in Adults

Transesophageal echocardiographic assessment of adult patients with complex congenital heart disease usually requires a meticulous sequential evaluation that requires the knowledge and experience of an advanced PTE echocardiographer. Although adult congenital heart lesions have not previously been included within the scope of basic cognitive echocardiographic skills,<sup>4</sup> several basic congenital lesions may have an impact on intraoperative care (as discussed under "Neurosurgery: Air Embolism") and should be recognized by a practitioner with basic PTE training. A patent foramen ovale and/or secundum atrial septal defect (ASD) is generally easily recognized via two-dimensional and color flow Doppler imaging in the ME bicaval view as a defect in the central portion of the IAS and should be considered in patients in whom there is high clinical suspicion of an otherwise unexplainable right-to-left shunt (hypoxia) or left-to-

right shunt.<sup>77,78</sup> However, an advanced PTE echocardiographer should be consulted if further echocardiographic interrogation of the entire IAS is warranted to exclude more complex congenital lesion of the IAS, including smaller secundum ASDs, primum ASDs, or more difficult to visualize sinus venous ASDs.<sup>77,78</sup>

Ventricular septal defects are classified on the basis of their location (perimembranous, muscular, double committed outlet, inlet) or their pathophysiology (postinfarction) and can be associated with significant hemodynamic instability. Although a basic echocardiographer may perform a basic PTE examination with two-dimensional and color flow Doppler using the ME four-chamber, ME two-chamber, and ME AV LAX views to evaluate a patient for a ventricular septal defect, this writing committee believes that this type of diagnostic interrogation usually requires advanced PTE skills. Thus, it is the recommendation of the writing committee that a physician trained in basic PTE echocardiography use a complete basic PTE examination to identify basic adult congenital heart disease as a potential mechanism for right-to-left or left-to-right shunts in a patient with unexplained hypoxia or hemodynamic instability. However, the echocardiographic diagnosis and directed intervention for more complex adult congenital heart disease, including ventricular septal defects and less commonly encountered ASDs, require consultation with an advanced PTE echocardiographer.<sup>77,78</sup>

## MAINTENANCE OF COMPETENCE AND QUALITY ASSURANCE

After an anesthesiologist echocardiographer has obtained basic PTE certification, he or she should continue to perform a minimum of 25 examinations per year to maintain his or her skills and competence level.<sup>4,5,79,80</sup> Maintenance of competence by regularly participating in local or national echocardiographic continuing medical education approved conferences or training courses is strongly recommended.

Each basic PTE examination should be organized according to current professional standards regarding image acquisition, image storage, and reporting.<sup>8</sup> All hospital-based ultrasound systems should allow for recording data onto a media format that allows offline review and archiving. At a minimum, the initial basic PTE examination should be stored, and any changes resulting in therapeutic interventions should be documented. The basic PTE examination should be documented as a paper or computer-generated report. The written or computer-generated report of the findings should be placed in the patient's medical record as soon as possible, and no later than before leaving the operating room. If the patient's medical condition requires emergent transfer to the intensive care unit or another location, an initial verbal reporting of the findings may be acceptable, followed by the written or electronic report as soon as the patient's medical condition permits.

The report should contain the following information<sup>2</sup>:

1. the date and time of the study;
2. the name and hospital identification number of the patient;
3. the patient's date of birth, age and gender;
4. the indication for the study;
5. documentation of informed consent;
6. the names of the performing and interpreting physicians;
7. findings;
8. impression;
9. any known complications of the examination;
10. the date and time the report was signed; and
11. the mode of archiving of the study.



## CONCLUSIONS

To date, a definitive document describing a basic PTE examination sequence that can be used by anesthesiologists for the evaluation of perioperative hemodynamic instability in surgical patients has not been available. Guidelines recommending a methodology for performing a basic PTE examination on the basis of a series of 11 anatomically referenced cross-sectional images are described, along with applicable clinical indications, to promote training in basic PTE echocardiography and consistency across patient populations and institutions.

## NOTICE AND DISCLAIMER

This report is made available by the ASE and the SCA as a courtesy reference source for members. This report contains recommendations only and should not be used as the sole basis to make medical practice decisions or for disciplinary action against any employee. The statements and recommendations contained in this report are based primarily on the opinions of experts, rather than on scientifically verified data. The ASE and the SCA make no express or implied warranties regarding the completeness or accuracy of the information in this report, including the warranty of merchantability or fitness for a particular purpose. In no event shall the ASE or the SCA be liable to you, your patients, or any other third parties for any decision made or action taken by you or such other parties in reliance on this information. Nor does your use of this information constitute the offering of medical advice by the ASE or the SCA or create any physician-patient relationship between the ASE or the SCA and your patients or anyone else.

## APPENDIX

### Members of the Council on Perioperative Echocardiography

Scott T. Reeves, MD, MBA, FASE, Chairman  
Madhav Swaminathan, MD, FASE, Vice Chairman  
Kathryn E. Glas, MD, MBA, FASE, Immediate Past Chair  
Mark S. Adams, BS, RDCS, FASE  
Mary Beth Brady, MD, FASE  
Alan C. Finley, MD  
Rebecca T. Hahn, MD, FASE  
Marsha Roberts, RCS, RDCS, FASE  
David Rubenson, MD, FASE  
Stanton K. Shernan, MD, FASE  
Doug Shook, MD, FASE  
Roman Sniecinski, MD, FASE  
Nikolaos J. Skubas, MD, FASE  
Christopher A. Troianos, MD  
Jennifer D. Walker, MD  
Will S. Whitley, MD

## REFERENCES

- Labovitz AJ, Noble VE, Bierig M, Goldstein SA, Jones R, Kort S, et al. Focused cardiac ultrasound in the emergent setting: a consensus statement of the American Society of Echocardiography and American College of Emergency Physicians. *J Am Soc Echocardiogr* 2010;23:1225-30.
- Mertens L, Seri I, Marek J, Arlettaz R, Barker P, McNamara P, et al. Targeted neonatal echocardiography in the neonatal intensive care unit: practice guidelines and recommendations for training. Writing Group of the American Society of Echocardiography (ASE) in collaboration with the European Association of Echocardiography (EAE) and the Association for European Pediatric Cardiologists (AEPC). *J Am Soc Echocardiogr* 2011;24:1057-78.
- Matsumoto M, Oka Y, Strom J, Frishman W, Kadish A, Becker RM, et al. Application of transesophageal echocardiography to continuous intraoperative monitoring of left ventricular performance. *Am J Cardiol* 1980;46:95-105.
- Practice guidelines for perioperative transesophageal echocardiography. A report by the American Society of Anesthesiologists and the Society of Cardiovascular Anesthesiologists Task Force on Transesophageal Echocardiography. *Anesthesiology* 1996;84:986-1006.
- Cahalan MK, Stewart W, Pearlman A, Goldman M, Sears-Rogan P, Abel M, et al. American Society of Echocardiography and Society of Cardiovascular Anesthesiologists task force guidelines for training in perioperative echocardiography. *J Am Soc Echocardiogr* 2002;15:647-52.
- Shanewise JS, Cheung AT, Aronson S, Stewart WJ, Weiss RL, Mark JB, et al. ASE/SCA guidelines for performing a comprehensive intraoperative multiplane transesophageal echocardiography examination: recommendations of the American Society of Echocardiography Council for Intraoperative Echocardiography and the Society of Cardiovascular Anesthesiologists Task Force for Certification in Perioperative Transesophageal Echocardiography. *Anesth Analg* 1999;89:870-84.
- Practice guidelines for perioperative transesophageal echocardiography. An updated report by the American Society of Anesthesiologists and the Society of Cardiovascular Anesthesiologists Task Force on Transesophageal Echocardiography. *Anesthesiology* 2010;112:1084-96.
- Mathew JP, Glas K, Troianos CA, Sears-Rogan P, Savage R, Shanewise J, et al. American Society of Echocardiography/Society of Cardiovascular Anesthesiologists recommendations and guidelines for continuous quality improvement in perioperative echocardiography. *J Am Soc Echocardiogr* 2006;19:1303-13.
- Kallmeyer IJ, Collard CD, Fox JA, Body SC, Shernan SK. The safety of intraoperative transesophageal echocardiography: a case series of 7200 cardiac surgical patients. *Anesth Analg* 2001;92:1126-30.
- Hogue CW Jr, Lappas GD, Creswell LL, Ferguson TB Jr, Sample M, Pugh D, et al. Swallowing dysfunction after cardiac operations. Associated adverse outcomes and risk factors including intraoperative transesophageal echocardiography. *J Thorac Cardiovasc Surg* 1995;110:517-22.
- Lennon MJ, Gibbs NM, Weightman WM, Leber J, Ee HC, Yusoff IF. Transesophageal echocardiography-related gastrointestinal complications in cardiac surgical patients. *J Cardiothorac Vasc Anesth* 2005;19:141-5.
- Daniel WG, Erbel R, Kasper W, Visser CA, Engberding R, Sutherland GR, et al. Safety of transesophageal echocardiography. A multicenter survey of 10,419 examinations. *Circulation* 1991;83:817-21.
- Egleston CV, Wood AE, Gorey TF, McGovern EM. Gastrointestinal complications after cardiac surgery. *Ann R Coll Surg Engl* 1993;75:52-6.
- Kharasch ED, Sivarajan M. Gastroesophageal perforation after intraoperative transesophageal echocardiography. *Anesthesiology* 1996;85:426-8.
- Hilberath JN, Oakes DA, Shernan SK, Bulwer BE, D'Ambra MN, Eltzschig HK. Safety of transesophageal echocardiography. *J Am Soc Echocardiogr* 2010;23(11):1115-27.
- Lang RM, Badano LP, Tsang W, Adams DH, Agricola E, Buck T, et al. EAE/ASE recommendations for image acquisition and display using three-dimensional echocardiography. *J Am Soc Echocardiogr* 2012;25:3-46.
- Lang RM, Bierig M, Devereux RB, Flachskampf FA, Foster E, Pellikka PA, et al. Recommendations for chamber quantification: a report from the American Society of Echocardiography's Guidelines and Standards Committee and the Chamber Quantification Writing Group, developed in conjunction with the European Association of Echocardiography, a branch of the European Society of Cardiology. *J Am Soc Echocardiogr* 2005;18:1440-63.
- Fleisher LA, Beckman JA, Brown KA, Calkins H, Chaikof EL, Fleischmann KE, et al. ACC/AHA 2007 guidelines on perioperative cardiovascular evaluation and care for noncardiac surgery: a report of the American College of Cardiology/American Heart Association Task Force



- on Practice Guidelines (Writing Committee to Revise the 2002 Guidelines on Perioperative Cardiovascular Evaluation for Noncardiac Surgery) developed in collaboration with the American Society of Echocardiography, American Society of Nuclear Cardiology, Heart Rhythm Society, Society of Cardiovascular Anesthesiologists, Society for Cardiovascular Angiography and Interventions, Society for Vascular Medicine and Biology, and Society for Vascular Surgery. *J Am Coll Cardiol* 2007;50:e159-242.
19. Couture P, Denault AY, McKenty S, Boudreault D, Plante F, Perron R, et al. Impact of routine use of intraoperative transesophageal echocardiography during cardiac surgery. *Can J Anaesth* 2000;47:20-6.
20. Forrest AP, Lovelock ND, Hu JM, Fletcher SN. The impact of intraoperative transesophageal echocardiography on an unselected cardiac surgical population: a review of 2343 cases. *Anaesth Intensive Care* 2002;30:734-41.
21. Minhaj M, Patel K, Muzic D, Tung A, Jeevanandam V, Raman J, et al. The effect of routine intraoperative transesophageal echocardiography on surgical management. *J Cardiothorac Vasc Anesth* 2007;21:800-4.
22. Kolev N, Brase R, Swanevelde J, Oppizzi M, Riesgo MJ, van der Maaten JM, et al. European Perioperative TOE Research Group. The influence of transoesophageal echocardiography on intra-operative decision making. A European multicentre study. *Anaesthesia* 1998;53:767-73.
23. Qaddoura FE, Abel MD, Mecklenburg KL, Chandrasekaran K, Schaff HV, Zehr KJ, et al. Role of intraoperative transesophageal echocardiography in patients requiring coronary artery bypass graft surgery. *Ann Thorac Surg* 2004;78:1586-90.
24. Heidenreich PA, Stainback RF, Redberg RF, Schiller NB, Cohen NH, Foster E. Transesophageal echocardiography predicts mortality in critically ill patients with unexplained hypotension. *J Am Coll Cardiol* 1995;26:152-8.
25. Oh JK, Seward JB, Khandheria BK, Gersh BJ, McGregor CG, Freeman WK, et al. Transesophageal echocardiography in critically ill patients. *Am J Cardiol* 1990;66:1492-5.
26. Memtsoudis SG, Rosenberger P, Löffler M, Eltzhig HK, Mizuguchi A, Shernan SK, et al. The usefulness of transesophageal echocardiography during intraoperative cardiac arrest in noncardiac surgery. *Anesth Analg* 2006;102:1653-7.
27. Brandt RR, Oh JK, Abel MD, Click RL, Orszulak TA, Seward JB. Role of emergency intraoperative transesophageal echocardiography. *J Am Soc Echocardiogr* 1998;11:972-7.
28. Shillcutt SK, Markin NW, Montzingo CR, Brakke TR. Use of rapid "rescue" perioperative echocardiography to improve outcomes after hemodynamic instability in noncardiac surgical patients. *J Cardiothorac Vasc Anesth* 2012;26:362-70.
29. Click RL, Abel MD, Schaff HV. Intraoperative transesophageal echocardiography: 5-year prospective review of impact on surgical management. *Mayo Clin Proc* 2000;75:241-7.
30. Denault AY, Couture P, McKenty S, Boudreault D, Plante F, Perron R, et al. Perioperative use of transesophageal echocardiography by anesthesiologists: impact in noncardiac surgery and in the intensive care unit. *Can J Anaesth* 2002;49:287-93.
31. Hofer CK, Zollinger A, Rak M, Matter-Ensner S, Klagofer R, Pasch T, et al. Therapeutic impact of intra-operative transoesophageal echocardiography during noncardiac surgery. *Anaesthesia* 2004;59:3-9.
32. Schulmeyer MC, Santelices E, Vega R, Schmied S. Impact of intraoperative transesophageal echocardiography during noncardiac surgery. *J Cardiothorac Vasc Anesth* 2006;20:768-71.
33. Eltzhig HK, Rosenberger P, Löffler M, Fox JA, Aranki SF, Shernan SK. Impact of intraoperative transesophageal echocardiography on surgical decisions in 12,566 patients undergoing cardiac surgery. *Ann Thorac Surg* 2008;85:845-52.
34. Still RJ, Hilgenberg AD, Akins CW, Daggett WM, Buckley MJ. Intraoperative aortic dissection. *Ann Thorac Surg* 1992;53:374-9.
35. Troianos CA, Savino JS, Weiss RL. Transesophageal echocardiographic diagnosis of aortic dissection during cardiac surgery. *Anesthesiology* 1991;75:149-53.
36. Reichert CL, Visser CA, van den Brink RB, Koolen JJ, van Wezel HB, Moulijn AC, et al. Prognostic value of biventricular function in hypotensive patients after cardiac surgery as assessed by transesophageal echocardiography. *J Cardiothorac Vasc Anesth* 1992;6:429-32.
37. Ellis J, Lichtor J, Feinstein S, Chung MR, Polk SL, Broelsch C, et al. Right heart dysfunction, pulmonary embolism and paradoxical embolization during liver transplantation. *Anesth Analg* 1989;68:777-82.
38. Suriani RJ, Cutrone A, Feierman D, Konstadt S. Intraoperative TEE during liver transplantation. *J Cardiothorac Vasc Anesth* 1996;10:699-707.
39. Wax DB, Torres A, Scher C, Leibowitz AB. TEE utilization in high-volume liver transplantation centers in the United States. *J Cardiothorac Vasc Anesth* 2008;6:811-3.
40. Cheung AT, Savino JS, Weiss SJ, Aukburg SJ, Berlin JA. Echocardiographic and hemodynamic indexes of left ventricular preload in patients with normal and abnormal ventricular function. *Anesthesiology* 1994;81:376-87.
41. Schmidlin D, Jenni R, Schmid ER. Transesophageal echocardiographic area and Doppler flow velocity measurements: comparison with hemodynamic changes in coronary artery bypass surgery. *J Cardiothorac Vasc Anesth* 1999;13:143-9.
42. Swenson JD, Harkin C, Pace NL, Astle K, Bailey P. Transesophageal echocardiography: an objective tool in defining maximum ventricular response to intravenous fluid therapy. *Anesth Analg* 1996;83:1149-53.
43. Thys DM, Hillel Z, Goldman ME, Mindich BP, Kaplan JA. A comparison of hemodynamic indices derived by invasive monitoring and two-dimensional echocardiography. *Anesthesiology* 1987;67:630-4.
44. Girard F, Couture P, Boudreault D, Normandin L, Denault A, Girard D. Estimation of the pulmonary capillary wedge pressure from transesophageal pulsed Doppler echocardiography of pulmonary venous flow: influence of the respiratory cycle during mechanical ventilation. *J Cardiothorac Vasc Anesth* 1998;12:16-21.
45. Ali MM, Royse AG, Connolly K, Royse CF. The accuracy of transoesophageal echocardiography in estimating pulmonary capillary wedge pressure in anaesthetised patients. *Anaesthesia* 2012;67:122-31.
46. Zoghbi WA, Enriquez-Sarano M, Foster E, Grayburn PA, Kraft CD, Levine RA, et al. American Society of Echocardiography. Recommendations for evaluation of the severity of native valvular regurgitation with two-dimensional and Doppler echocardiography. *J Am Soc Echocardiogr* 2003;16:777-802.
47. Baumgartner H, Hung J, Bermejo J, Chambers JB, Evangelista A, Griffin BP, et al. Echocardiographic assessment of valve stenosis: EAE/ASE recommendations for clinical practice. *J Am Soc Echocardiogr* 2009;22:1-23.
48. Pruszczyk P, Torbicki A, Kuch-Wocial A, Chlebus M, Miskiewicz ZC, Jedrusik P. Transoesophageal echocardiography for definitive diagnosis of haemodynamically significant pulmonary embolism. *Eur Heart J* 1995;16:534-8.
49. Pruszczyk P, Torbicki A, Pacho R, Chlebus M, Kuch-Wocial A, Pruszyński B, et al. Noninvasive diagnosis of suspected severe pulmonary embolism: transesophageal echocardiography vs spiral CT. *Chest* 1997;112:722-8.
50. Rosenberger P, Shernan SK, Body SC, Eltzhig HK. Utility of intraoperative transesophageal echocardiography for diagnosis of pulmonary embolism. *Anesth Analg* 2004;99:12-6.
51. Krivec B, Voga G, Zuran I, Skale R, Pareznik R, Podbregar M, et al. Diagnosis and treatment of shock due to massive pulmonary embolism: approach with transesophageal echocardiography and intrapulmonary thrombolysis. *Chest* 1997;112:1310-6.
52. Torbicki A, Perrier A, Konstantinides S, Agnelli G, Galie N, Pruszczyk P, et al. Guidelines on the diagnosis and management of acute pulmonary embolism: the Task Force for the Diagnosis and Management of Acute Pulmonary Embolism of the European Society of Cardiology (ESC). *Eur Heart J* 2008;29:2276-315.
53. McConnell MV, Solomon SD, Rayan ME, Come PC, Goldhaber SZ, Lee RT. Regional right ventricular dysfunction detected by echocardiography in acute pulmonary embolism. *Am J Cardiol* 1996;78:469-73.
54. Papadopoulos G, Kuhly P, Brock M, Rudolph KH, Link J, Eylich K. Venous and paradoxical air embolism in the sitting position. A prospective study with transoesophageal echocardiography. *Acta Neurochir (Wien)* 1994;126:140-3.

55. Cucchiara RF, Nugent M, Seward JB, Messick JM. Air embolism in upright neurosurgical patients: detection and localization by two-dimensional transesophageal echocardiography. *Anesthesiology* 1984;60:353-5.
56. Mammoto T, Hayashi Y, Ohnishi Y, Kuro M. Incidence of venous and paradoxical air embolism in neurosurgical patients in the sitting position: detection by transesophageal echocardiography. *Acta Anaesthesiol Scand* 1998;42:643-7.
57. Fathi AR, Eshtehardi P, Meier B. Patent foramen ovale and neurosurgery in sitting position: a systematic review. *Br J Anaesth* 2009;102:588-96.
58. Black S, Muzzi DA, Nishimura RA, Cucchiara RF. Preoperative and intraoperative echocardiography to detect right-to-left shunt in patients undergoing neurosurgical procedures in the sitting position. *Anesthesiology* 1990;72:436-8.
59. Kirkpatrick AW, Sirois M, Laupland KB, Liu D, Rowan K, Ball CG, et al. Hand-held thoracic sonography for detecting post-traumatic pneumothoraces: the Extended Focused Assessment with Sonography for Trauma (EFAST). *J Trauma* 2004;57(2):288-95.
60. Helling TS, Duke P, Beggs CW, Crouse LJ. A prospective evaluation of 68 patients suffering blunt chest trauma for evidence of cardiac injury. *J Trauma* 1989;29:961-5.
61. Helling TS, Wilson J, Augustosky K. The utility of focused abdominal ultrasound in blunt abdominal trauma: a reappraisal. *Am J Surg* 2007;194:728-32.
62. Bahner D, Blaivas M, Cohen HL, Fox JC, Hoffenberg S, Kendall J, et al. AUM practice guideline for the performance of the Focused Assessment With Sonography for Trauma (FAST) examination. *J Ultrasound Med* 2008;27:313-8.
63. Minard G, Schurr MJ, Croce MA, Gavant ML, Kudsk KA, Taylor MJ, et al. A prospective analysis of transesophageal echocardiography in the diagnosis of traumatic disruption of the aorta. *J Trauma* 1996;40:225-30.
64. Saletta S, Lederman E, Fein S, Singh A, Kuehler DH, Fortune JB. Transesophageal echocardiography for the initial evaluation of the widened mediastinum in trauma patients. *J Trauma* 1995;39:137-41.
65. Shapiro MJ, Yanofsky SD, Trapp J, Durham RM, Labovitz A, Sear JE, et al. Cardiovascular evaluation in blunt thoracic trauma using transesophageal echocardiography (TEE). *J Trauma* 1991;31:835-9.
66. Sparks MB, Burchard KW, Marrin CA, Bean CH, Nugent WC Jr., Plehn JF. Transesophageal echocardiography. Preliminary results in patients with traumatic aortic rupture. *Arch Surg* 1991;126:711-3.
67. Karalis DG, Victor MF, Davis GA, McAllister MP, Covaesky VA, Ross JJ Jr, et al. The role of echocardiography in blunt chest trauma: a transthoracic and transesophageal echocardiographic study. *J Trauma* 1994;36:53-8.
68. Ellis JE, Bender EM. Intraoperative transesophageal echocardiography in blunt thoracic trauma. *J Cardiothorac Vasc Anesth* 1991;5:373-6.
69. Vignon P, Gueret P, Vedrinne JM, Lagrange P, Cornu E, Abrieu O, et al. Role of transesophageal echocardiography in the diagnosis and management of traumatic aortic disruption. *Circulation* 1995;92:2959-68.
70. Mattox KL, Limacher MC, Feliciano DV, Colosimo L, O'Meara ME, Beall AC Jr, et al. Cardiac evaluation following heart injury. *J Trauma* 1985;25:758-65.
71. Beggs CW, Helling TS, Evans LL, Hays LV, Kennedy FR, Crouse LJ. Early evaluation of cardiac injury by two-dimensional echocardiography in patients suffering blunt chest trauma. *Ann Emerg Med* 1987;16:542-5.
72. Frazee RC, Mucha P Jr., Farnell MB, Miller FA Jr. Objective evaluation of blunt cardiac trauma. *J Trauma* 1986;26:510-20.
73. Garcia-Fernandez MA, Lopez-Perez JM, Perez-Castellano N, Quero LF, Virgos-Lamela A, Otero-Ferreiro A, et al. Role of transesophageal echocardiography in the assessment of patients with blunt chest trauma: correlation of echocardiographic findings with the electrocardiogram and creatine kinase monoclonal antibody measurements. *Am Heart J* 1998;135:476-81.
74. Hiatt JR, Yeatman LA Jr., Child JS. The value of echocardiography in blunt chest trauma. *J Trauma* 1988;28:914-22.
75. Mollod M, Felner JM. Transesophageal echocardiography in the evaluation of cardiothoracic trauma. *Am Heart J* 1996;132:841-9.
76. Weiss RL, Brier JA, O'Connor W, Ross S, Brathwaite CM. The usefulness of transesophageal echocardiography in diagnosing cardiac contusions. *Chest* 1996;109:73-7.
77. Lai WW, Geva T, Shirali GS, Frommelt PC, Humes RA, Brook MM, et al. Task Force of the Pediatric Council of the American Society of Echocardiography; Pediatric Council of the American Society of Echocardiography. Guidelines and standards for performance of a pediatric echocardiogram: a report from the Task Force of the Pediatric Council of the American Society of Echocardiography. *J Am Soc Echocardiogr* 2006;19:1413-30.
78. Lopez L, Colan SD, Frommelt PC, Ensing GJ, Kendall K, Younoszai AK, et al. Recommendations for quantification methods during the performance of a pediatric echocardiogram: a report from the Pediatric Measurements Writing Group of the American Society of Echocardiography Pediatric and Congenital Heart Disease Council. *J Am Soc Echocardiogr* 2010;23:465-95.
79. Quinones MA, Douglas PS, Foster E, Gorcsan J III, Lewis JF, Pearlman AS, et al. American College of Cardiology, American Heart Association, American College of Physicians-American Society of Internal Medicine, American Society of Echocardiography, Society of Cardiovascular Anesthesiologists, Society of Pediatric Echocardiography. ACC/AHA clinical competence statement on echocardiography: a report of the American College of Cardiology/American Heart Association/American College of Physicians-American Society of Internal Medicine Task Force on Clinical Competence. *J Am Coll Cardiol* 2003;41:687-708.
80. National Board of Echocardiography. Basic PTE®. Available at: <http://www.echoboards.org/content/basic-pte%C2%AE>. Accessed March 1, 2013.