

Recommendations for Quantification of Doppler Echocardiography: A Report From the Doppler Quantification Task Force of the Nomenclature and Standards Committee of the American Society of Echocardiography

Miguel A. Quiñones, MD, Chair, Catherine M. Otto, MD, Marcus Stoddard, MD,
Alan Waggoner, MHS, RDMS, and William A. Zoghbi, MD, *Raleigh, North Carolina*

INTRODUCTION

Doppler echocardiography is a noninvasive technique that provides unique hemodynamic information otherwise not available without invasive monitoring. The accuracy of the results depends, however, on meticulous technique and an understanding of Doppler principles and flow dynamics. This document provides recommendations based on the scientific literature and a consensus from a body of experts to guide the recording and measurement of Doppler data. The document is not a comprehensive review of all the clinical applications of Doppler echocardiography.

GENERAL PRINCIPLES

The Doppler principle states *that the frequency of reflected ultrasound is altered by a moving target, such as red blood cells*. The magnitude of this Doppler shift relates to the velocity of the blood cells, whereas the polarity of the shift reflects the direction of blood flow toward (positive) or away (negative) from the transducer. The Doppler equation

$$\Delta F = \frac{V \times 2F_o \times \cos \theta}{c} \quad (1)$$

states that the Doppler shift (ΔF) is directly propor-

tional to the velocity (V) of the moving target (ie, blood cells), the transducer frequency (F_o), and the cosine of the angle of incidence (θ) and is inversely proportional to the velocity of sound in tissue ($c = 1540$ m/s). The Doppler equation can be solved for blood flow velocity as follows:

$$V = \frac{\Delta F \times c}{2 F_o \times \cos \theta} \quad (2)$$

When solving the Doppler equation, an angle of incidence of 0 or 180 degrees (cosine = 1.0) is assumed for cardiac applications.

Currently, Doppler echocardiography consists of 3 modalities: pulsed wave (PW) Doppler, continuous wave (CW) Doppler, and color Doppler imaging. PW Doppler measures flow velocity within a specific site (or sample volume) but is limited by the aliasing phenomenon that prevents it from measuring velocities beyond a given threshold (called the Nyquist limit). CW Doppler, on the other hand, can record very high blood flow velocities but cannot localize the site of origin of these velocities along the pathway of the sound beam. Color flow Doppler uses PW Doppler technology but with the addition of multiple gates or regions of interest within the path of the sound beam. In each of these regions, a flow velocity estimate is superimposed on the 2-dimensional (2D) image with a color scale based on flow direction, mean velocity, and sometimes velocity variance.

Doppler echocardiography is used to evaluate blood flow velocity with red blood cells as the moving target. Current ultrasound systems can also apply the Doppler principle to assess velocity within cardiac tissue. The moving target in this case is tissue, such as myocardium, that has higher amplitude of backscatter ultrasound and a lower velocity compared with red blood cells. This new application is

Reprint requests: American Society of Echocardiography, 1500 Sunday Dr, Suite 102, Raleigh, NC 27607.

J Am Soc Echocardiogr 2002;15:167-84

Copyright © 2002 by the American Society of Echocardiography.
0894-7317/2002/\$35.00 + 0 27/1/120202

doi:10.1067/mje.2002.120202

called tissue Doppler and can be performed in the PW or the color mode. A comprehensive discussion of this new technology is beyond the scope of this document; however, some of the newer applications for measuring regional myocardial velocities that use the PW mode will be discussed.

Doppler echocardiography has 2 uses: detection and quantitation of normal and disturbed flow velocities. For detection purposes, all 3 modalities have high sensitivity and specificity. However, color flow Doppler often allows faster detection of abnormal flows and provides a spatial display of velocities in a 2D plane. Quantification of flow velocity is typically obtained with either PW or CW Doppler. Measuring velocity with color Doppler is possible, but the methods are still under development and have not been standardized across different brands of ultrasound equipment. (One exception is the proximal isovelocity surface acceleration method, used in the evaluation of valvular regurgitation.) The primary use of PW Doppler is to assess velocities across normal valves or vessels to evaluate cardiac function or calculate flow. Common applications include measurements of cardiac output (CO) and regurgitant volumes, quantitation of intracardiac shunts, and evaluation of diastolic function.

CW Doppler, on the other hand, is used to measure high velocities across restrictive orifices, such as stenotic or regurgitant valve orifices. These velocities are converted into pressure gradients by applying the simplified Bernoulli equation:

$$\text{pressure gradient} = 4V^2 \quad (3)$$

This equation has been demonstrated to be accurate in flow models, animal studies, and in the cardiac catheterization laboratory as long as the velocity proximal to the obstruction does not exceed 1.5 m/s. Common clinical applications include determining pressure gradients in stenotic native valves, estimating pulmonary artery (PA) systolic pressure from the velocity of tricuspid regurgitation (TR), and determining prosthetic valve gradients. The combination of PW and CW Doppler has been used with great accuracy to determine stenotic valve areas with the continuity equation.

An alternative technique also used for recording high flow velocities is the high pulse repetition frequency (PRF) modification of the PW Doppler. High PRF uses range ambiguity to increase the maximum velocity that can be detected with PW Doppler. Multiple sample volumes are placed proximal to

and at the depth of interest. PRF is determined by the depth of the most proximal sample volume, which allows measurement of higher velocities without signal aliasing at the depth of interest. Although the resulting spectral output includes frequencies from each of the sample volume depths, the origin of the high-velocity signal is inferred from other anatomic and physiologic data, as with CW Doppler.

RECOMMENDATIONS ON RECORDING AND MEASUREMENT TECHNIQUES

The accuracy of measuring blood cell velocities by Doppler relies on maintaining a parallel orientation between the sound waves and blood flow. Although most ultrasound systems allow correction of the Doppler equation for the angle of incidence, this measurement is difficult to perform accurately because of the 3-dimensional orientation of the blood flow. Angle correction is therefore not recommended. The Doppler sound beam should be oriented as parallel as possible to the flow, guided both by the 2D image (sometimes assisted by color flow imaging) and the quality of the Doppler recording. Small (<20 degrees) deviations in angle produce mild (<10%) errors in velocity measurements. Although these errors may be acceptable for low-velocity flows, when Doppler is used to derive pressure gradients even a small error in velocity measurement can lead to significant underestimation of the gradient because of the quadratic relation between velocity and pressure gradient.

PW Doppler

PW Doppler is used in combination with the 2D image to record flow velocities within discrete regions of the heart and great vessels. Measurements derived from these velocities are used to evaluate cardiac performance (Figure 1). The most common sites are the left ventricular outflow tract (LVOT), mitral annulus and left ventricular inflow (at the tips of the mitral valve leaflets), pulmonic valve annulus and PA, tricuspid valve inflow, hepatic veins, and pulmonary veins. The flow volume passing through these sites can be calculated as the product of the velocity-time integral (VTI) and the cross-sectional area (CSA) of the respective site. When recording velocities for flow measurements, the sample volume is placed at the same location as the 2D measurements of CSA. Adjust the sample volume axial

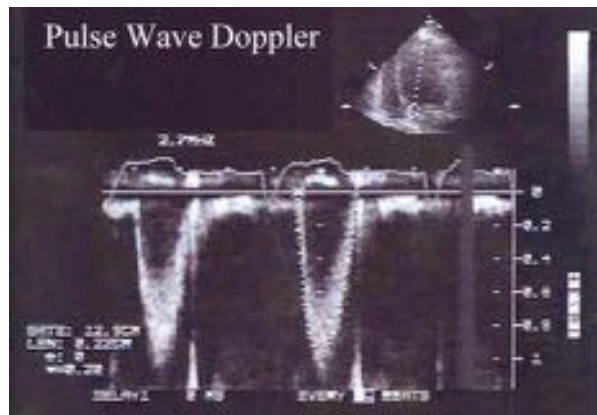


Figure 1 PW Doppler recording of left ventricular outflow track velocity obtained from apical window. Because flow is away from transducer, velocities are displayed below baseline. Notice narrow spectral pattern during flow acceleration and deceleration and wider dispersion seen during mid-systole. Degree of dispersion indicates range of blood flow velocities detected within sample volume.

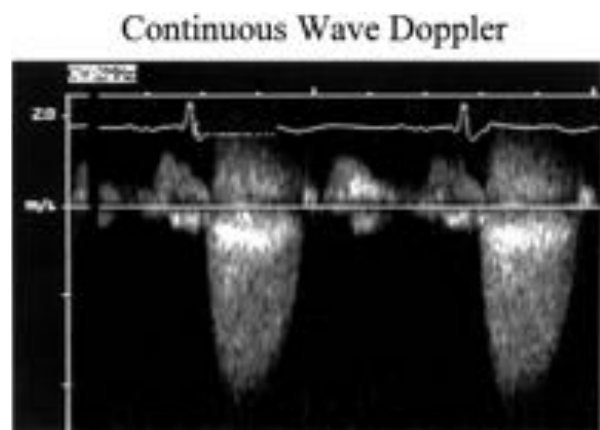


Figure 2 CW Doppler recording of velocity through aortic valve in patient with AS. Transducer position is at apex; thus systolic velocities are displayed below baseline. In diastole, positive mitral inflow velocities can be seen as inflow moves toward transducer. Note wide spectral dispersion of velocities during systole and diastole indicating that Doppler beam is detecting all flow velocities encountered along its course.

length to 5 to 7 mm and set the wall filters at low levels to ensure that lower velocities adjacent to the baseline are recorded for the timing of flow to be measured correctly. The velocities should be recorded over at least 2 or 3 respiratory cycles at a paper or sweep speed of 50 or 100 mm/s; the faster speed is essential for measurements that require precise time resolution, such as time intervals, integrals, and velocity slopes.

A typical PW Doppler velocity consists of a spectral recording of varying intensity, depending on the acoustic density of the reflected interface, ie, the mass of blood cells (Figure 1). The most dense (or brightest) portion of the spectral tracing represents the velocity of the majority of blood cells, also known as the modal velocity. Likewise, less dense areas depict the velocity of a lesser mass of blood cells. When measuring velocities, use the outer edge of the dense (or bright) envelope of the spectral recording.

CW Doppler

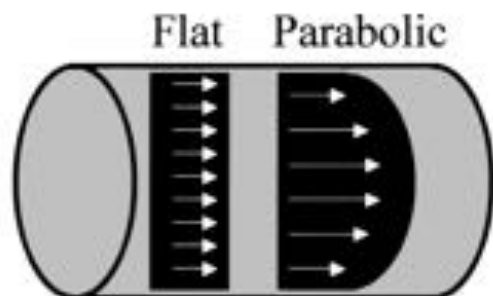
In contrast to PW Doppler, CW Doppler records the velocities of all the red blood cells moving along the path of the sound beam (Figure 2). Consequently, a CW Doppler recording always consists of a full spectral envelope with the outer border corresponding to the fastest moving blood cells. No simple guidelines guarantee a parallel orientation of the CW beam with blood flow in all instances. However, color flow Doppler can help determine the direction

of the jet in a 2D plane, particularly in regurgitant lesions. A nonimaging CW transducer is recommended to search for the highest velocity, particularly in aortic stenosis (AS), in which multiple windows of examination may be required to detect the highest velocity. Measurements of velocities recorded by CW Doppler are always taken from the outer border. The site of origin of a high-velocity jet is inferred from the particular lesion that is being examined. For instance, if the CW beam is directed through a stenotic aortic valve, the outer edge of the recording is assumed to represent the stenotic jet velocity. Therefore, only well-defined envelopes should be used for quantitation of velocities to obviate significant errors. These recommendations are also applied when high PRF is used to record a high-velocity jet, except that high PRF should be used in combination with the 2D image.

Color Flow Doppler

A comprehensive discussion of color flow Doppler is beyond the scope of this document. Nevertheless, the following are some basic recommendations that apply to any ultrasound machine. Processing the multigate Doppler information and creating the color pixels take a certain amount of time; therefore the larger the area of interest, the slower the frame rate. For this reason, a smaller area of interest should be used and depth settings kept at the lowest possi-

Flow Diagram



Flow = CSA x Velocity

Figure 3 Diagrammatic illustration of flow through a vessel showing 2 different flow profiles. Flat profile with all cells traveling at same velocity and parabolic profile with cells at center traveling faster than those on the side. At any given time, flow through the vessel represents product of average velocity of all cells multiplied by CSA of the vessel.

ble level that allows visualization of the structure in question. When high-velocity blood flows are analyzed, set the color scale at the maximum allowed for that given depth. Color Doppler gain should be set just below the threshold for noise.

RECOMMENDATIONS RELATING TO SPECIFIC CLINICAL USES

Flow Measurements

PW Doppler technique. Flow is derived as the product of CSA and the average velocity of the blood cells passing through the blood vessel or valve orifice during the flow period (Figure 3), whereas stroke volume (SV) represents the product of CSA and VTI. When PW Doppler is used, the velocities recorded within the sample volume will be affected by the flow profile. With current instrumentation, assessing flow profile or measuring the average velocity of the blood cells is difficult. Consequently, volume-flow measurements are most accurate when flow is laminar (ie, all blood cells are moving in the same direction) and the profile is flat. The most important technical factor to ensure accu-

Measurement of Stroke Volume LV Outflow

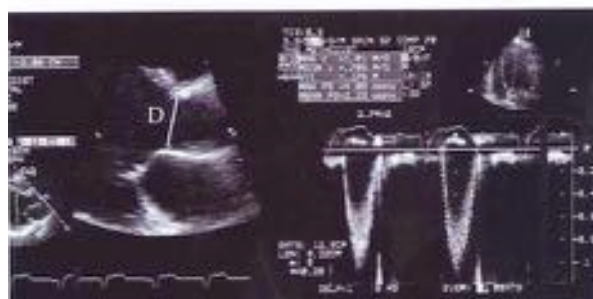


Figure 4 Method used in determining systolic flow volume through left ventricular outflow.

racy of measurements is to properly match the site of velocity recording with the anatomic measurement of the CSA.¹ For this reason, it is preferable to use sites where the CSA does not change significantly during the flow period and can be determined accurately from the 2D image and where the flow profile is likely to be flat. When tracing the velocity to derive a VTI, it is best to trace the outer edge of the most dense (or brightest) portion of the spectral tracing (ie, the modal velocity) and ignore the dispersion that occurs near peak velocity. For patients in sinus rhythm, data from 3 to 5 cardiac cycles may be averaged. However, in patients with irregular rhythms such as atrial fibrillation, 5 to 10 cycles may be required to ensure accuracy of results.

The preferred sites for determining SV and cardiac output (in descending order of preference) are as follows:

1. The LVOT tract or aortic annulus
2. The mitral annulus
3. The pulmonic annulus

The LVOT is the most widely used site.² SV is derived as:

$$SV = CSA \times VTI \quad (4)$$

The CSA of the aortic annulus is circular, with little variability during systole. Because the area of a circle = πr^2 , the area of the aortic annulus is derived from the annulus diameter (D) measured in the parasternal long-axis view as:

$$CSA = D^2 \times \pi/4 = D^2 \times 0.785 \quad (5)$$

Image the LV outflow with the expanded or zoom

Measurement of Stroke Volume Mitral Annulus

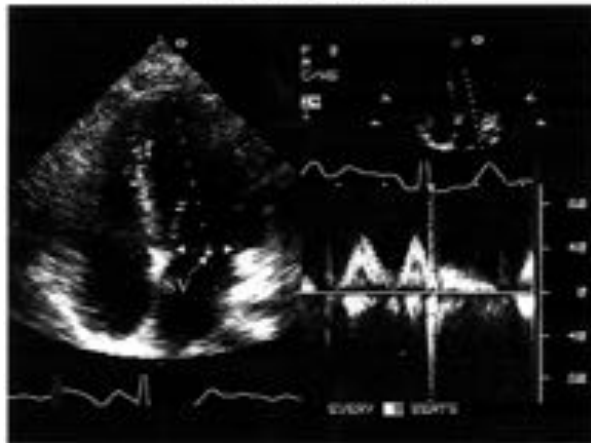

Figure 5 Method used in determining diastolic flow volume through mitral annulus.

option and place 1 or 2 beats in a cine loop (Figure 4). This imaging allows a more precise measurement of the annulus diameter during early systole from the junction of the aortic leaflets with the septal endocardium, to the junction of the leaflet with the mitral valve posteriorly, using inner edge to inner edge. The largest of 3 to 5 measurements should be taken because the inherent error of the tomographic plane is to underestimate the annulus diameter. When serial measurements of SV and CO are being performed, use the baseline annulus measurement for the repeated studies because little change in annulus size occurs in adults over time.

The LV outflow velocity is recorded from the apical 5-chamber or long-axis view, with the sample volume positioned about 5 mm proximal to the aortic valve (Figure 4). The opening click of the aortic valve or spectral broadening of the signal should not be viewed in mid-systole because this means the sample volume is into the region of proximal acceleration. The closing click of the aortic valve is often seen when the sample volume is correctly positioned.

The LVOT method should not be applied when the landmarks needed to measure the annulus diameter cannot be properly visualized or if evidence of LV outflow obstruction exists because the velocities recorded will not be matched to the CSA of the aortic annulus.

Flow across the mitral annulus is measured in the apical 4-chamber view with equation 4 (Figure

Measurement of Stroke Volume Pulmonic Annulus

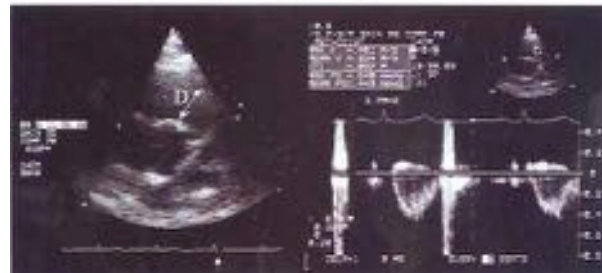

Figure 6 Method used in determining systolic flow volume through pulmonic annulus.

5). Although the mitral annulus is not perfectly circular, applying a circular geometry (equation 5) gives similar or better results than attempting to derive an elliptical CSA with measurements taken from multiple views.^{2,3} The diameter of the mitral annulus should be measured from the base of the posterior and anterior leaflets during early to mid-diastole, 1 frame after the leaflets begin to close after its initial opening. The sample volume is positioned so that in diastole it is at the level of the annulus.

The pulmonic annulus is probably the most difficult of the 3 sites, mostly because the poor visualization of the annulus diameter limits its accuracy and the right ventricular (RV) outflow tract contracts during systole. Measure the annulus during early ejection (2 to 3 frames after the R wave on the electrocardiogram) from the anterior corner to the junction of the posterior pulmonic leaflet with the aortic root (Figure 6).^{4,5} Equations 4 and 5 are used to derive SV and CSA, respectively.

When learning to measure flow volumes across the above sites, make measurements in all 3 sites in patients without regurgitant lesions or intracardiac shunts because the flow through these sites should be equal. Doing this will develop expertise needed to apply these methods accurately. In regurgitant valve lesions, the forward flow through the regurgitant valve is greater than through the other valves, and the difference between them is equivalent to the regurgitant flow. Regurgitant fraction, an index of severity of regurgitation, is derived as regurgitant flow (in milliliters) divided by the forward flow across the regurgitant valve. In the presence of significant left-to-right intracardiac shunts, flow measurements can calculate the pulmonic to systemic (Qp:Qs) flow ratio. For example, in a

Doppler Assessment of Diastolic Function

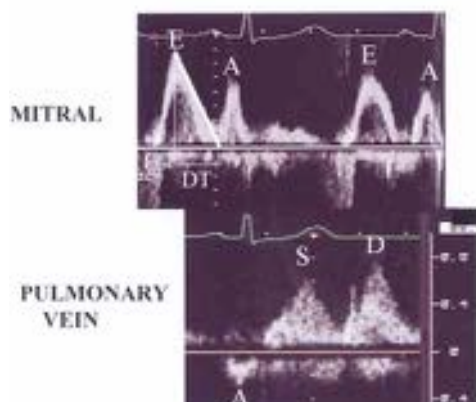


Figure 7 Example of transmitral and pulmonary vein velocity recordings in a healthy subject. Pulmonary vein velocity recording has been aligned in time with mitral velocity for illustration purposes.

patient with an atrial-septal defect, pulmonic flow will be much higher than aortic flow; the ratio of the two is equivalent to the Qp:Qs ratio. In the best of hands, these calculations may have up to a 20% error.

Flow measurements with CW Doppler. Recordings of flow velocity through the above sites are also possible with CW Doppler. In addition, flow velocity can be recorded in the ascending aorta from the suprasternal notch.⁶ The main difficulty with CW Doppler is that the velocity envelope reflects the highest velocity of the moving blood cells. This, in turn, is affected by the flow profile and the smallest CSA of flow. For example, when recording the LV outflow velocity from the apical window by CW, the velocity integral is related to the CSA of the aortic valve rather than the annulus.⁷ The area of the valve is more difficult to derive with 2D imaging.

A primary application of Doppler is in the serial evaluation of SV and CO. Given that the CSA is relatively stable in the same patient, the VTI can accurately track changes in SV. The day-to-day variability of velocity measurements appears to be less with CW than with PW Doppler.⁸

Application of Flow Measurements in the Evaluation of Diastolic Function

Left ventricle. PW Doppler recordings of the mitral and pulmonary vein velocities can provide insight into the dynamics of LV filling and help evaluate diastolic function (Figure 7).⁹⁻¹¹ Importantly,

Isovolumic Relaxation Time - CW

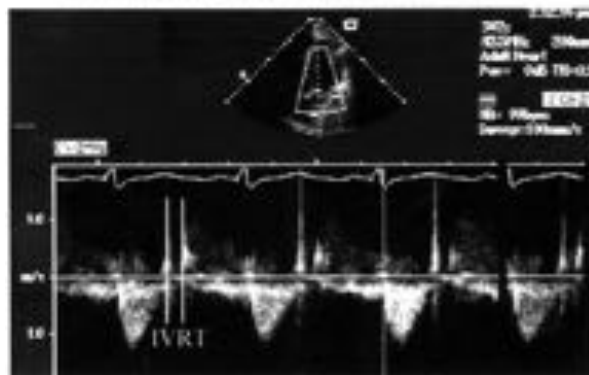


Figure 8 Method used for measuring IVRT from recording of LV outflow and inflow velocities with CW Doppler. Transducer is at cardiac apex, and Doppler cursor is aligned in intermediate position between aortic and mitral valves.

changes in these velocities occur with alterations in left atrial and LV diastolic pressures.¹²⁻¹⁸ In addition, the transmitral velocity, together with tricuspid and hepatic vein velocities, is useful when evaluating cardiac tamponade and constrictive pericarditis.¹⁹⁻²³

Mitral inflow velocity. Parameters of diastolic function that reflect changes in flow should be measured from recordings of the inflow velocity at the mitral annulus, where the CSA is more stable. On the other hand, parameters that relate to the transmitral gradient are best obtained at the tips of the valve leaflets. The measurements obtained are divided into 3 categories: (1) absolute velocities such as E and A velocities, (2) time intervals such as acceleration and deceleration times, and (3) time-velocity integrals such as the integrals of the E and A velocities, respectively. The ratio of these integrals to the total integral of flow velocity is used as an index of the respective filling fractions. The first 2 categories are best measured at the tips of the valve leaflets, whereas the third is more accurate from the mitral annulus site.

An additional index of diastolic function is the isovolumic relaxation time (IVRT), defined as the interval from the closure of the aortic valve to the opening of the mitral valve. This interval can be accurately measured by Doppler with either PW or CW Doppler. With PW Doppler, the transducer is angulated into the apical 5-chamber or long-axis view and the sample volume placed within the LVOT, but in proximity to the anterior mitral valve (MV) leaflet to record both inflow and outflow sig-

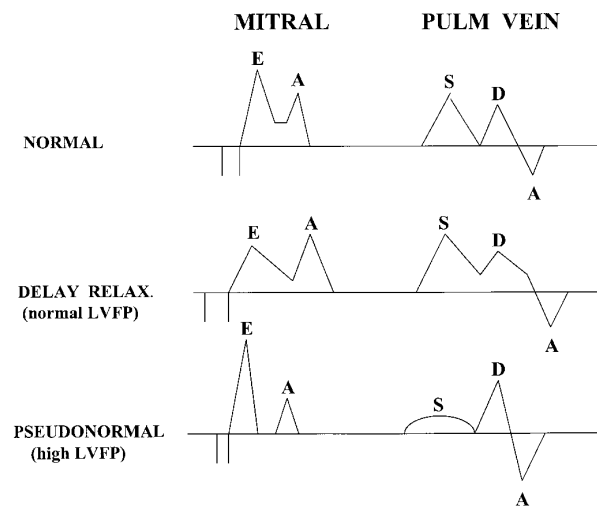


Figure 9 Diagrammatic illustration of 3 common patterns of mitral and pulmonary vein velocities: normal, delayed relaxation, and pseudonormal.

nals. With CW Doppler, IVRT is measured by aiming the Doppler beam at an intermediate position between inflow and outflow to record both velocities (Figure 8). IVRT is measured as the interval between the end of ejection and the onset of mitral inflow. As a rule, CW recordings provide a more reproducible measure of IVRT than PW. Three to 5 cardiac cycles should be averaged when measuring transmitral velocities and IVRT. One exception to this rule is made in conditions in which these velocities change with respiration, such as in pericardial constriction or tamponade. In these cases, the velocities should be recorded with a respiratory tracing and averaged separately.

Certain patterns have been associated with changes in left atrial pressures in patients with LV disease, particularly those with depressed systolic function (Figure 9).^{16,17} With normal pressures, the transmitral velocity, as a rule, has a lower E than A velocity with a prolonged IVRT and deceleration time, reflecting the impaired relaxation of the left ventricle. On the other hand, with higher left atrial pressures, the E velocity increases whereas the IVRT and deceleration time shorten. This resembles the pattern seen in healthy young persons and thus it is referred to as pseudonormal.

Pulmonary vein velocity. Analysis of the pulmonary vein velocities can provide insight into the diastolic properties of the LV and the function of the left atrium. Certain patterns have been associated with increased left atrial pressures in patients with

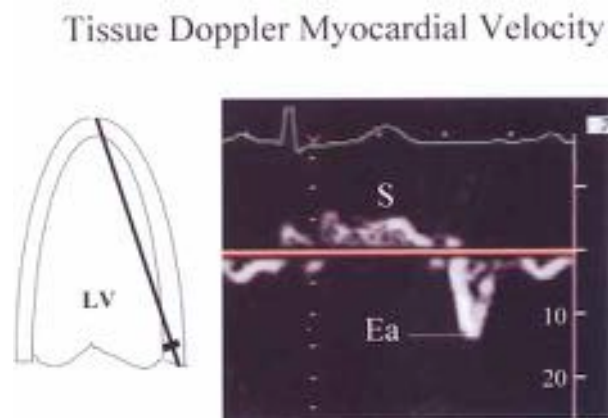


Figure 10 Myocardial velocity recording obtained from apical window with tissue Doppler using PW mode. Diagram illustrates Doppler cursor with sample volume positioned at base of lateral wall. Recording shows systolic positive wave (S), early diastolic wave (E_m), and atrial wave (A_m).

LV disease, particularly those with depressed systolic function, that complement the information derived from the mitral inflow velocity (Figure 9).^{16,17} With current technology, the velocity of flow within the pulmonary veins can be recorded from the transthoracic apical view in 80% of patients. The most common vein accessible from this window is the right upper pulmonary vein. The flow within the vein can be visualized with color Doppler using a lower velocity scale (<40 cm/s) and the PW sample volume can be placed inside the vein. Without attention to proper sample volume location, 2 errors commonly occur. The sample volume can be placed near the opening of the pulmonary vein but still within the left atrium, or the low-velocity motion of the posterior atrial wall can be recorded. When recording the pulmonary veins, keep the wall filters at a low level.

The flow velocity measurements currently recommended in the pulmonary veins are the peak systolic (S), peak diastolic (D), and atrial reversal (A) velocities, the S/D ratio, and the duration of the A velocity (Figures 7 and 9).

Myocardial and annular velocities. Longitudinal velocities within the myocardium can be recorded with tissue Doppler from the apical window with the PW mode. A small (<5 mm) sample volume is placed within a myocardial segment and a spectral recording of velocities within the segment obtained (Figure 10). For optimal recording of tissue velocity, both gains and filter settings should be set low.

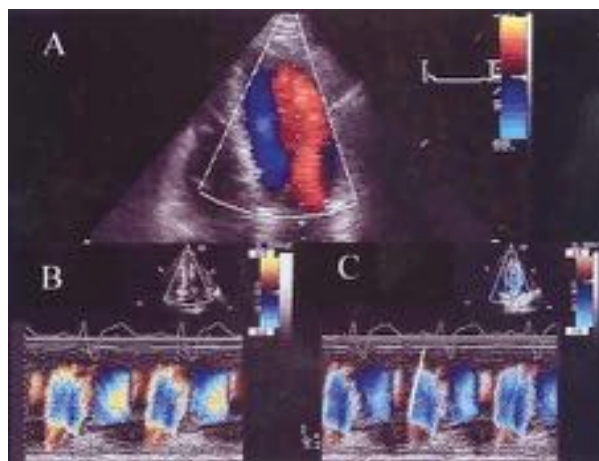


Figure 11 Demonstration of method used to measure flow propagation velocity using color M-mode. In panel A, 2D color Doppler frame with M-mode cursor aligned in center of red inflow velocities is shown. Panels B and C illustrate color M-mode tracing obtained through cursor at 2 different aliasing velocities obtained by shifting 0 baseline. This maneuver enhances appreciation of the propagation velocity.

Myocardial velocities are highest at the base and lowest toward the apex. Consequently, the velocities at the basilar segments are commonly used to assess the function of the corresponding wall. The sample volume is usually placed at the junction of the LV wall with the mitral annulus.

The spectral longitudinal velocity of the myocardium normally consists of a positive systolic wave and 2 diastolic peaks, one during early diastole and a second during atrial contraction (Figure 10). The early diastolic velocity (E_m ; also referred to as E_a for annular velocity) has been demonstrated to be an index of LV relaxation that is relatively insensitive to left atrial pressure.²⁴⁻²⁶ Although E_m can be measured in any ventricular wall, the lateral wall and septum have been more commonly used in the evaluation of diastolic function. The ratio of transmitral E velocity to E_m has been recently demonstrated to relate well with mean left atrial (or pulmonary capillary wedge) pressure in multiple clinical scenarios, such as depressed or normal systolic LV function, hypertrophic cardiomyopathy, sinus tachycardia, and atrial fibrillation.²⁶⁻³⁰

Flow propagation velocity. Color Doppler can record an early inflow velocity across the MV from the apical 4-chamber view (Figure 11). An M-mode cursor placed in the center of the brightest inflow velocity can record a color M-mode of the inflow jet

Hepatic vein velocity

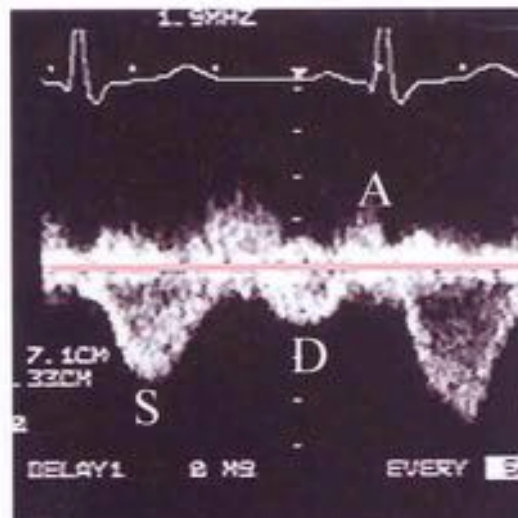


Figure 12 Normal hepatic vein velocity recorded from subcostal window. From this window, a negative velocity indicates antegrade flow moving toward RA. Notice that antegrade systolic velocity is larger than antegrade diastolic velocity. Small retrograde atrial (A) velocity is also seen. These velocities are subject to variation with respiration.

as it moves from the mitral inflow area toward the apex. Adjusting the color Doppler baseline can highlight a color edge, the slope of which represents the propagation velocity of blood flowing toward the apex. This flow propagation velocity has been shown to relate inversely with the time constant of LV relaxation and to be fairly insensitive to changes in left atrial pressures.^{31,32} In a manner analogous to the E_m velocity, the ratio of transmitral E to flow propagation velocity relates to mean left atrial (or pulmonary capillary wedge) pressure.^{33,34}

Right ventricle

Tricuspid inflow velocity. As with the mitral inflow, the tricuspid inflow velocity reflects the atrioventricular diastolic pressure-flow interactions on the right side of the heart. Tricuspid flow velocities, however, are also affected by respiration; thus all measurements taken must be averaged throughout the respiratory cycle or recorded at end-expiratory apnea. The tricuspid inflow velocity is best recorded from either a low parasternal RV inflow view or from the apical 4-chamber view.

The same measurements derived from the mitral inflow velocity can be measured in the tricuspid.

However, to date, there are fewer investigations available on the application of these measurements in the evaluation of RV diastolic function. RV IVRT has not been used as an index of diastolic function because it is significantly altered by pulmonary hypertension and difficult to measure with Doppler alone.

Hepatic vein flow velocity. The velocity of flow in the hepatic veins can be recorded from the subcostal window with the flow oriented parallel to the sound waves (Figure 12). The normal pattern of flow velocity consists of systolic and diastolic antegrade flow velocities (S and D waves, respectively) and a retrograde A velocity. Each of these waves being profoundly altered by the 2 phases of respiration. The influence of respiration differs between disease states. These variations may be used to differentiate between restrictive and constrictive pericardial disorders.²²

Estimation of Right-sided Pressures

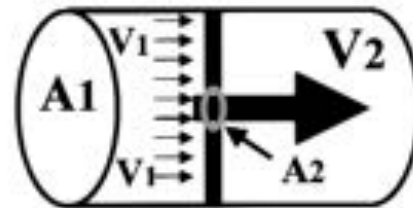
When TR is present, application of the $4V^2$ equation to the peak TR velocity provides a close estimate of the peak pressure gradient between RV and right atrium (RA).³⁵ Consequently, RV systolic pressure can be derived by adding an estimate of mean RA pressure to the peak RV-RA gradient. The mean RA pressure is estimated with the magnitude of the inferior vena cava collapse, with inspiration and variations in the hepatic vein velocities.³⁶⁻³⁸ In the absence of pulmonic stenosis, the peak RV pressure is equivalent to the PA systolic pressure. In the presence of pulmonic stenosis, the PA systolic pressure is estimated by subtracting the maximal pulmonic valve pressure gradient, derived from the velocity across the valve by CW Doppler, from the peak RV systolic pressure. The accuracy of these pressure estimates depends on recording a clear envelope of the TR velocity by CW Doppler. If the signal is incomplete, significant underestimation of the peak TR velocity will occur. The quality of the TR velocity recording may be enhanced with contrast echocardiography by injecting agitated saline solution or other contrast echocardiographic agents intravenously.³⁹

Varying degrees of pulmonic regurgitation (PR) are common, particularly in cardiac patients. The velocity of PR reflects the instantaneous gradient between PA and RV. Thus, the PR velocity at end-diastole may be used to derive the PA diastolic pressure with the $4V^2$ equation and adding to the pressure gradient an estimate of mean RA pressure.

The RV outflow and pulmonic flow velocities are often altered in the presence of significant pul-

Continuity Equation

$$\text{Flow (Q)} = \text{CSA} \times \text{Velocity}$$



$$Q_1 = Q_2$$

$$Q_1 = A_1 \times V_1 = A_2 \times V_2$$

$$A_2 = Q_1 / V_2$$

Figure 13 Diagrammatic representation of continuity equation. When laminar flow encounters a small discrete stenosis, it must accelerate rapidly to pass through small orifice. Flow proximal to stenosis is same as flow passing through stenosis. Because flow equals velocity times CSA, area of stenotic orifice can be solved if velocity through orifice and flow is known.

monary hypertension. The acceleration time is shortened, and a mid-systolic notch in the flow velocity envelope is often present. An inverse curvilinear relation exists between the acceleration time and mean PA pressure from which regression equations have been developed. The 95% confidence limits of the estimate of PA pressure with these equations are, however, too wide for accurate clinical use and are therefore not recommended.

Pressure Gradients and Valve Areas

Recommendations on the use of CW Doppler for recording high-velocity jets have been previously discussed. The modified Bernoulli equation, $4V^2$, is very accurate in estimating the pressure gradient across a restrictive orifice under most physiologic conditions.⁴⁰⁻⁴³ The exceptions are as follows: (1) a velocity proximal to the stenosis greater than 1.5 m/s; (2) the presence of 2 stenotic areas proximal to each other, for example, subpulmonic stenosis combined with valvular stenosis; and (3) the presence of a long tunnel-like stenotic lesion.

In stenotic lesions, the jet velocity can derive the

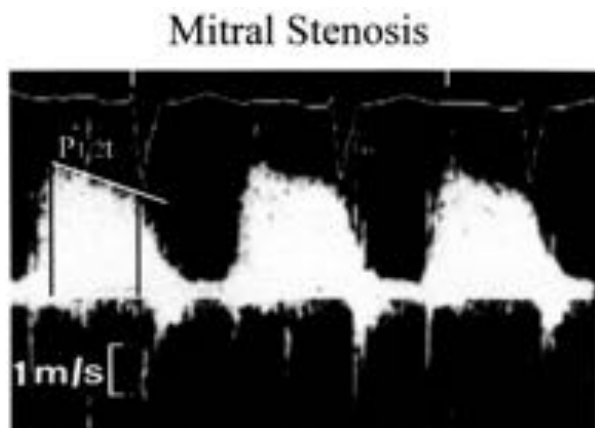


Figure 14 CW Doppler tracing taken from a patient with mitral stenosis, illustrating measurement of pressure half time.

peak instantaneous and the mean pressure gradient across the stenosis. The mean gradient is obtained by averaging the instantaneous gradients. Current ultrasound systems contain software to derive the peak velocity, VTI, and mean gradients from a tracing of the velocity envelope. It is important to include both heart rate and rhythm when reporting valve gradients. The Doppler equation is fairly accurate in deriving the pressure gradient across a tight stenosis. However, in AS the phenomenon of pressure recovery may result in a higher gradient by Doppler than the gradient measured by catheter, particularly if the distal pressure is recorded several centimeters away from the stenotic valve. In practice, the error is small and of minimal clinical significance.

Valve area measurements with the continuity equation. The continuity equation states that the flow passing through a stenotic valve is equal to the flow proximal to the stenosis (Figure 13). Given that flow equals velocity multiplied by CSA, if flow is known the area of stenosis can be derived as:

$$\text{Stenotic area} = \text{Flow/Velocity across stenosis} \quad (6)$$

AS is the most common lesion for which the continuity equation is used.^{4,44,45} The flow volume represents the SV across the aortic valve, determined at the LV outflow. In AS, however, the sample volume must be positioned carefully to not be within the prestenotic flow acceleration region. Place the sample volume 1 cm proximal to the aortic valve while recording the velocity. Then, slowly move the sample

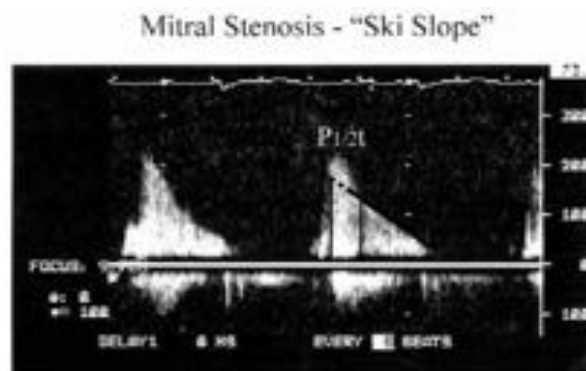


Figure 15 CW Doppler recording of transmitral velocity in a patient with mitral stenosis. Velocity pattern shows rapid early deceleration that decelerates to mid-diastole, giving rise to "ski slope" appearance. In these cases, estimating pressure half time from the slower component of velocity descent is better, as illustrated in second cardiac cycle.

volume toward the valve until an increase in velocity and spectral broadening is seen. Thereafter, the sample volume is moved back until a narrow band of flow velocities is obtained. The denominator of the continuity equation is the integral of the stenotic jet. Consequently, the maximal AS velocity must be recorded by aligning the CW beam as parallel as possible to the stenotic jet. This is best accomplished with a nonimaging CW transducer that uses multiple windows of interrogation.

In mitral stenosis, the continuity equation is useful in situations for which the pressure half-time method is limited. However, in this lesion accurately determining flow across the mitral annulus is difficult. SV is therefore measured at the aortic annulus and used in the numerator of the equation; the denominator is the integral of the mitral stenosis jet. The method is quite accurate in the absence of associated mitral regurgitation (MR).⁵

Mitral valve area with the pressure half-time method. The pressure half-time (P1/2t) method is a simple and accurate method of determining valve area in mitral stenosis (Figure 14). Pressure half-time represents the time that the maximal pressure gradient takes to decrease by one half. When expressed in terms of velocity, this time is equivalent to the time that the peak stenotic velocity takes to drop by 30%. Early studies established an inverse relation between P1/2t and mitral valve area (MVA),⁴⁶ and from this relation the following empirical equation was derived:

$$\text{MVA} = 220/\text{P1/2t} \quad (7)$$

Aortic Regurgitation- Pressure Half Time

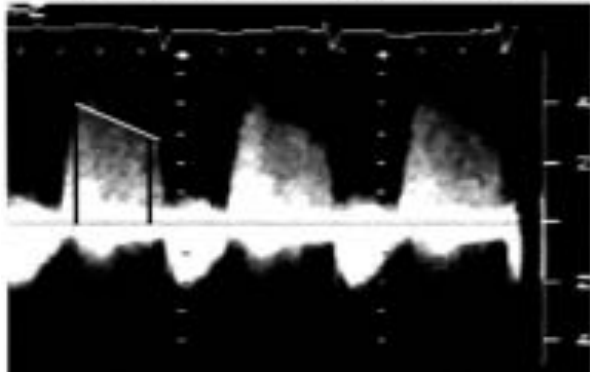


Figure 16 CW Doppler tracing of aortic regurgitation velocity illustrating method for determining pressure half time.

This formula works surprisingly well in most patients and can be reliably used in clinical decision making.^{47,48} Potential sources of errors must be considered, such as rapid heart rate, the presence of significant aortic regurgitation, and conditions that alter left atrial or LV compliance and/or LV relaxation.⁴⁹⁻⁵¹ In some patients, the early velocity descent is curvilinear rather than linear, resembling a ski slope. In these instances, derive a pressure-half time by extrapolating the mid-diastolic linear descent backward, as illustrated in Figure 15. Although there are similarities between mitral and tricuspid stenosis, the P1/2t method has not been as extensively validated for the calculation of tricuspid valve area.

Application of Doppler in Regurgitant Valve Lesions

Doppler echocardiography is the most commonly used diagnostic technique for detecting and evaluating valvular regurgitation. Multiple indexes have been developed to assess severity of regurgitation with PW, CW, and color Doppler. Although techniques for measuring these indexes are described in this document, recommendations concerning their clinical application will be discussed in an upcoming document dedicated to the evaluation of regurgitant valve lesions.

Regurgitant volume, regurgitant fraction, and effective regurgitant orifice area. In the presence of valvular regurgitation, the flow through the affected valve is greater than through other competent valves. For example, in MR more volume will pass through the MV than through the aortic or pulmonic

Effect of Central Jets

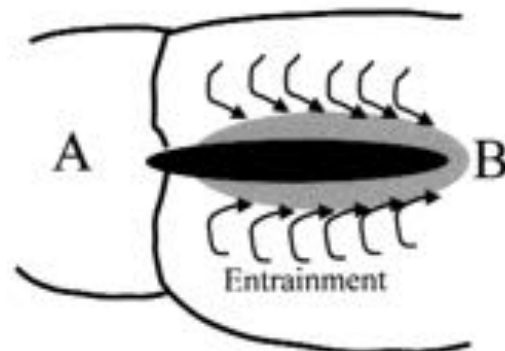


Figure 17 Diagrammatic illustration explaining concept of entrainment. Flow is passing from chamber A to chamber B through discrete stenosis that generates high-velocity jet. Initial high-velocity jet is depicted in black. As high-velocity flow enters receiving chamber, blood that sits in that chamber is forced into motion. Blood cells will move in a circular fashion around high-velocity jet and will be encoded by color Doppler. Jet in receiving chamber becomes wider. In case of mitral valve regurgitation, this phenomenon will make regurgitant jet area appear larger than expected for a given volume of regurgitation.

valves. The difference between the two represents the regurgitant volume. Regurgitant fraction is derived from the regurgitant volume divided by the flow through the regurgitant valve.^{3,52} Careful measurement of flow volumes through the annular sites described can determine the calculation of regurgitant volume and regurgitant fraction.

Effective regurgitant orifice area (EROA) is a new index of regurgitation derived with the continuity equation:

$$\text{EORA} = \text{Regurgitant volume} / \text{Regurgitant VTI} \quad (8)$$

where the regurgitant VTI is the integral of the regurgitant velocity recorded by CW Doppler.⁵³

Application of pressure half time in aortic regurgitation. Recording of aortic regurgitation jet by CW Doppler reflects the instantaneous pressure differential between the aorta and left ventricle. Thus, the rate of velocity decline from its early peak to late diastole is an index of severity of aortic regurgitation. Although this rate of decline may be measured as a slope, it is more commonly assessed by measuring pressure half time in a manner analogous to mitral stenosis; that is, the time taken for the peak velocity to decline by 30% (Figure 16).⁵⁴ To accu-

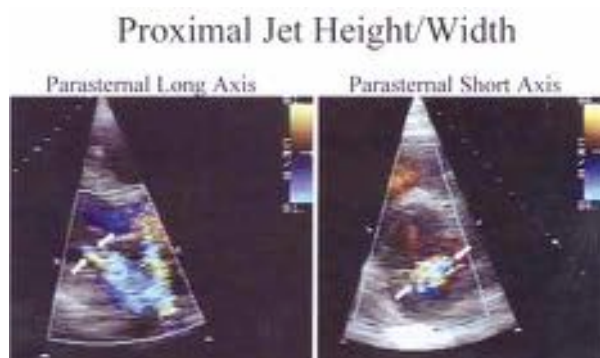

Figure 18 Color Doppler recording of MR in parasternal long-axis (*left*) and short-axis (*right*) view. Measurement of jet height and width is illustrated by *arrows*.

rately measure this index, a complete envelope of the regurgitant jet must be recorded by CW and the peak velocity should be 4 m/s or greater. In addition to the severity of regurgitation, other hemodynamic factors such as LV diastolic compliance and systemic vascular resistance can alter the rate of decline of the regurgitant velocity.

Application of color flow Doppler. Color flow Doppler imaging is widely used to detect regurgitant valve lesions. The area of color Doppler flow velocity disturbance in the receiving chamber provides a semiquantitative evaluation of regurgitant severity. Trivial and mild degrees of regurgitation, as a rule, have thin jets that travel short distances into the receiving chamber; more severe lesions have broader jets covering larger areas within the receiving chamber. However, the regurgitant jet area is seriously limited by numerous technical and physiologic variables that affect the length and width of the regurgitant jet. Jets that are centrally directed into a receiving chamber tend to have a larger color jet area for a given flow because of entrainment of blood cells inside the receiving chamber (Figure 17). On the other hand, eccentric jets traveling along a wall will lose energy and have a smaller color area for a given flow.⁵⁵ Regurgitant jet area should therefore be used with caution when assessing severity of regurgitant lesions. Furthermore, when assessing valve regurgitation, set the aliasing threshold in the color scale to the highest possible level to limit the effect of entrainment on the regurgitant jet area.

Parameters derived from the color flow velocities within the regurgitant orifice appear to be more accurate than the color jet area in evaluating severity of regurgitation.⁵⁶⁻⁵⁸ To assess these parameters

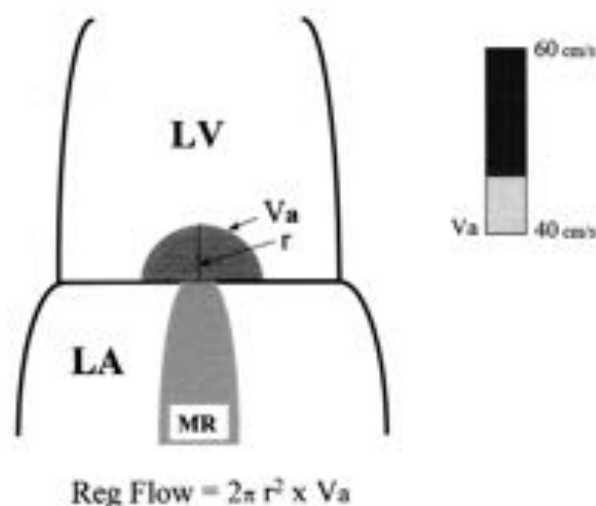


Figure 19 Diagrammatic representation of concept of PISA used to assess severity of MR.

well, image the regurgitant site in multiple longitudinal and cross-sectional planes, paying meticulous attention to imaging the velocities within the regurgitant orifice. Both the width and the area of the regurgitant jet at the valve orifice (ie, near the vena contracta) or immediately distal to the orifice relate well with other independent measurements of severity of regurgitation (Figure 18).⁵⁶⁻⁵⁸ Examination of the flow velocity pattern proximal to the regurgitant orifice provides insight into the severity of regurgitation. Proximal flow acceleration occurs with the isovelocity "surfaces" assuming a hemispheric shape adjacent to the regurgitant orifice that can be visualized with color Doppler (Figure 19).⁵⁹⁻⁶² The velocity in this proximal isovelocity surface area (PISA) is equal to the aliasing velocity (V_a). Regurgitant flow (in milliliters per second) can be derived from the PISA radius (r) as $2\pi r^2 \times V_a$. Assuming the maximal PISA radius occurs simultaneously with the peak regurgitant flow and the peak regurgitant velocity (PkV_{reg}), the EORA is derived as:

$$EORA = (2\pi r^2 \times V_a) / PkV_{reg} \quad (9)$$

Regurgitant volume can be estimated as EORA multiplied by regurgitant VTI.⁶³

The above calculations can be accurately performed only if the region of PISA appears hemispheric. To ensure this, the sound waves should be oriented parallel to flow and the color Doppler baseline shifted toward the direction of regurgitant flow

until a semicircular area of PISA is well visualized. This method is therefore easier to apply to regurgitant lesions involving the MV, particularly those with centrally directed jets.

Evaluating Prosthetic Valves

The general principles for evaluating prosthetic valve function are similar to those of native valve stenosis. Because a prosthetic valve in general has a smaller effective area than the corresponding normal native valve, higher velocities, and therefore pressure gradients, are recorded through the prosthesis compared with a native valve. Velocities and gradients through prosthetic valves depend on valve type and size, flow, and heart rate.^{64,65} Thus, reporting heart rate in addition to other parameters should be part of the routine assessment of prosthetic valve function. Overall, pressure gradients by Doppler and by catheter measurements correlate well.⁶⁶ However, in certain valve prostheses, specifically bileaflet valves, overestimation of gradients by Doppler has been demonstrated, particularly for smaller sized prostheses.^{67,68}

The technique of recording adequate velocities through prosthetic valves is similar to that of native valves, with special attention directed toward minimizing the angle of incidence between the Doppler beam and flow velocity. For prostheses in the mitral or tricuspid position, this is performed from the apical or low parasternal window and can be guided with color flow imaging. However, some cases, because of an unusual position of the valve or presence of obstruction, have an eccentric inflow jet (or jets). In these cases the window of examination should be modified accordingly. For aortic valve prostheses, recording from all available windows, including apical, right sternal border, suprasternal, and subcostal, is encouraged to avoid an error in flow angulation and underestimation of gradients. This recording is particularly important in stenotic prosthetic valves, for which the stenotic jet may be eccentric, similar to native AS.

Prosthetic aortic valve function. Because gradients depend on flow (among other factors), the continuity equation is also applied to prosthetic valves. For prosthetic aortic valves, measurement of flow is usually performed with the apical 5-chamber or long-axis view, with the sample volume positioned within 1 cm proximal to the valve. By the continuity equation, effective aortic valve area can be derived as SV divided by the time-velocity integral of the jet. For determination of SV, measure the diameter of the LVOT; but in difficult cases, the sewing ring diameter can be

substituted for the LVOT diameter, recognizing that it may yield a higher value for the effective valve area.^{65,69}

Doppler-derived effective valve areas have been shown to relate to valve size and have been reported for few prostheses. A Doppler velocity index, derived as the ratio of peak velocity in the LVOT to the peak velocity through the prosthesis, is less dependent on valve size. This index is especially useful if the valve size is not known at the time of the study.^{65,68}

Prosthetic mitral and tricuspid valve function. Mean gradients for several types of mitral prostheses and more recently for tricuspid prostheses, have been reported. Effective valve area has been derived for prosthetic MVs with the P1/2t formula. However, the constant of 220 has been derived for native MVs, not for prosthetic MVs.⁷⁰ As with native valves, the P1/2t method has limitations similar to those previously discussed but is useful in detecting prosthetic valve obstruction.⁷¹ In cases in which discordance between gradients and effective area is apparent, application of the continuity equation may be beneficial.⁷² No data are available for the application of the continuity equation in tricuspid valves.

Prosthetic valve regurgitation. For the most part, all the currently used mechanical valves have a minimal degree of functional ("built-in") regurgitation that, at times, is detected with Doppler ultrasound and should not be confused with pathologic regurgitation.^{73,74} Regurgitation of prosthetic aortic valves is readily detected by transthoracic Doppler echocardiography, and its severity is assessed by several modalities in a manner analogous to native aortic insufficiency. Because of the position of the prosthetic MV in relation to the transducer and the regurgitant chamber, considerable ultrasound shadowing and Doppler flow masking occurs during transthoracic studies in these patients. This scenario is more severe in mechanical valves compared with bioprosthetic valves. Thus, transthoracic color and conventional Doppler are less sensitive for the detection of prosthetic MV regurgitation.^{75,76} A nonimaging CW transducer should be used in all patients with prosthetic MVs because the lower frequency sound wave has better penetration and can often record a regurgitant jet that has not been detected with the imaging transducer. In patients with a mechanical St. Jude's mitral prosthesis, a peak early velocity of 1.9 m/s or greater without other signs of obstruction is 90% sensitive and 89% specific for significant valve regurgitation.⁷⁷ Transesophageal echo-

cardiography is often needed to confirm this lesion and assess the severity of regurgitation. For the most part, prosthetic tricuspid valve regurgitation is easier to detect than MR.

SUMMARY AND CONCLUSIONS

Doppler echocardiography provides an accurate assessment of the severity of many cardiac disorders and has therefore assumed an integral role in the clinical evaluation of cardiac patients. This document emphasizes the appropriate methods to properly record and quantify Doppler velocities. However, expertise in the performance of Doppler echocardiography can only be obtained by appropriate training, practice, and experience. Lastly, the field of echocardiography is dynamic and continues to evolve rapidly. Therefore, future modifications of these recommendations will be created as newer methods and applications of Doppler echocardiography emerge.

REFERENCES

1. Zoghbi WA, Quiñones MA. Determination of cardiac output by Doppler echocardiography: a critical appraisal. *Herz* 1986;11:258-68.
2. Lewis JF, Kuo LC, Nelson JG, Limacher MC, Quiñones MA. Pulsed Doppler echocardiographic determination of stroke volume and cardiac output: clinical validation of two new methods using the apical window. *Circulation* 1984;70:425-31.
3. Enriquez-Sarano M, Bailey KR, Seward JB, Tajik AJ, Krohn MJ, Mays JM. Quantitative Doppler assessment of valvular regurgitation. *Circulation* 1993;87:841-8.
4. Zoghbi WA, Farmer KL, Soto JG, Nelson JG, Quiñones MA. Accurate noninvasive quantification of stenotic aortic valve area by Doppler echocardiography. *Circulation* 1986;73:452-9.
5. Nakatani S, Masuyama T, Kodama K, Kitabatake A, Fujii K, Kamada T. Value and limitations of Doppler echocardiography in the quantification of stenotic mitral valve area: comparison of the pressure half-time and the continuity equation methods. *Circulation* 1988;77:78-85.
6. Huntsman LL, Stewart DK, Barnes SR, Franklin SB, Colocousis JS, Hessel EA. Noninvasive Doppler determination of cardiac output in man: clinical validation. *Circulation* 1983;67:593-602.
7. Bouchard A, Blumlein S, Schiller NB, Schlitt S, Byrd BF 3d, Ports T, et al. Measurement of left ventricular stroke volume using continuous wave Doppler echocardiography of the ascending aorta and M-mode echocardiography of the aortic valve. *J Am Coll Cardiol* 1987;9:75-83.
8. Moulinier L, Vener T, Schiller NB, Kurtz TW, Morris RC Jr, Sebastian A. Measurement of aortic blood flow by Doppler echocardiography: day to day variability in normal subjects and applicability in clinical research. *J Am Coll Cardiol* 1991;17:1326-33.
9. Rokey R, Kuo LC, Zoghbi WA, Limacher MC, Quiñones MA. Determination of parameters of left ventricular diastolic filling with pulsed Doppler echocardiography: comparison with cineangiography. *Circulation* 1985;71:543-50.
10. Stoddard MF, Pearson AC, Kern MJ, Ratcliff J, Mrosek DG, Labovitz AJ. Left ventricular diastolic function: comparison of pulsed Doppler echocardiographic and hemodynamic indexes in subjects with and without coronary artery disease. *J Am Coll Cardiol* 1989;13:327-36.
11. Nishimura RA, Abel MD, Hatle LK, Tajik AJ. Assessment of diastolic function of the heart: background and current applications of Doppler echocardiography: part II, clinical studies [review]. *Mayo Clin Proc* 1989;64:181-204.
12. Appleton CP, Hatle LK, Popp RL. Relation of transmitral flow velocity patterns to left ventricular diastolic function: new insights from a combined hemodynamic and Doppler echocardiographic study. *J Am Coll Cardiol* 1988;12:426-40.
13. Mulvagh S, Quiñones MA, Kleiman NS, Cheirif J, Zoghbi WA. Estimation of left ventricular end-diastolic pressure from Doppler transmitral flow velocity in cardiac patients independent of systolic performance. *J Am Coll Cardiol* 1992;20:112-9.
14. Pozzoli M, Capomolla S, Pinna G, Cobelli F, Tavazzi L. Doppler echocardiography reliably predicts pulmonary artery wedge pressure in patients with chronic heart failure with and without mitral regurgitation. *J Am Coll Cardiol* 1996;27:883-93.
15. Nishimura RA, Abel MD, Hatle LK, Tajik AJ. Relation of pulmonary vein to mitral flow velocities by transesophageal Doppler echocardiography: effect of different loading conditions. *Circulation* 1990;81:1488-97.
16. Kuecherer HF, Muhiudeen IA, Kusumoto FM, Lee E, Moulinier LE, Cahalan MK, et al. Estimation of mean left atrial pressure from transesophageal pulsed Doppler echocardiography of pulmonary venous flow. *Circulation* 1990;82:1127-39.
17. Appleton CP, Galloway JM, Gonzalez MS, Gaballa M, Basnight MA. Estimation of left ventricular filling pressures using two-dimensional and Doppler echocardiography in adult patients with cardiac disease: additional value of analyzing left atrial size, left atrial ejection fraction and the difference in duration of pulmonary venous and mitral flow velocity at atrial contraction. *J Am Coll Cardiol* 1993;22:1972-82.
18. Nagueh SF, Kopelen HA, Zoghbi WA. Feasibility and accuracy of Doppler echocardiographic estimation of pulmonary artery occlusive pressure in the intensive care unit. *Am J Cardiol* 1995;75:1256-62.
19. Burstow DJ, Oh JK, Bailey KR, Seward JB, Tajik AJ. Cardiac tamponade: characteristic Doppler observations. *Mayo Clin Proc* 1989;64:312-24.
20. Chandraratna PA. Echocardiography and Doppler ultrasound in the evaluation of pericardial disease. *Circulation* 1991;84:(Suppl I):I303-I310.
21. Hatle LK, Appleton CP, Popp RL. Differentiation of constrictive pericarditis and restrictive cardiomyopathy by Doppler echocardiography [comments]. *Circulation* 1989;79:357-70.
22. Oh JK, Hatle LK, Seward JB, Danielson GK, Schaff HV, Reeder GS, et al. Diagnostic role of Doppler echocardiogra-

- phy in constrictive pericarditis [comments]. *J Am Coll Cardiol* 1994;23:154-62.
23. Cohen GI, Pietrolungo JF, Thomas JD, Klein AL. A practical guide to assessment of ventricular diastolic function using Doppler echocardiography [review]. *J Am Coll Cardiol* 1996;27:1753-60.
24. Oki T, Tabata T, Yamada H, Wakatsuki T, Shinohara H, Nishikado A, et al. Clinical application of pulsed Doppler tissue imaging for assessing abnormal left ventricular relaxation [comments]. *Am J Cardiol* 1997;79:921-8.
25. Sohn DW, Chai IH, Lee DJ, Kim HC, Kim HS, Oh BH, et al. Assessment of mitral annulus velocity by Doppler tissue imaging in the evaluation of left ventricular diastolic function. *J Am Coll Cardiol* 1997;30:474-80.
26. Nagueh SF, Middleton KJ, Kopelen HA, Zoghbi WA, Quiñones MA. Doppler tissue imaging: a noninvasive technique for evaluation of left ventricular relaxation and estimation of filling pressures. *J Am Coll Cardiol* 1997;30:1527-33.
27. Ommen SR, Nishimura RA, Appleton CP, Miller FA, Oh JK, Redfield MM, et al. Clinical utility of Doppler echocardiography and tissue doppler imaging in the estimation of left ventricular filling pressures: a comparative simultaneous Doppler-catheterization study. *Circulation* 2000;102:1788-94.
28. Nagueh SF, Lakkis NM, Middleton KJ, Spencer WH 3d, Zoghbi WA, Quiñones MA. Doppler estimation of left ventricular filling pressures in patients with hypertrophic cardiomyopathy. *Circulation* 1999;99:254-61.
29. Nagueh SF, Mikati I, Kopelen HA, Middleton KJ, Quiñones MA, Zoghbi WA. Doppler estimation of left ventricular filling pressure in sinus tachycardia: a new application of tissue doppler imaging. *Circulation* 1998;98:1644-50.
30. Oki T, Iuchi A, Tabata T, Mishiyo Y, Yamada H, Abe M, et al. Left ventricular systolic wall motion velocities along the long and short axes measured by pulsed tissue Doppler imaging in patients with atrial fibrillation. *J Am Soc Echocardiogr* 1999;12:121-8.
31. Brun P, Tribouilloy C, Duval AM, Iserin L, Meguira A, Pelle G, et al. Left ventricular flow propagation during early filling is related to wall relaxation: a color M-mode Doppler analysis. *J Am Coll Cardiol* 1992;20:420-32.
32. Garcia MJ, Smedira NG, Greenberg NL, Main M, Firstenberg MS, Odabashian J, et al. Color M-mode Doppler flow propagation velocity is a preload insensitive index of left ventricular relaxation: animal and human validation. *J Am Coll Cardiol* 2000;35:201-8.
33. Garcia MJ, Ares MA, Asher C, Rodriguez L, Vandervoort P, Thomas JD. An index of early left ventricular filling that combined with pulsed Doppler peak E velocity may estimate capillary wedge pressure. *J Am Coll Cardiol* 1997;29:448-54.
34. Nagueh SF, Kopelen HA, Quiñones MA. Assessment of left ventricular filling pressures by Doppler in the presence of atrial fibrillation. *Circulation* 1996;94:2138-45.
35. Currie PJ, Seward JB, Chan KL, Fyfe DA, Hagler DJ, Mair DD, et al. Continuous wave Doppler determination of right ventricular pressure: a simultaneous Doppler-catheterization study in 127 patients. *J Am Coll Cardiol* 1985;6:750-6.
36. Kircher BJ, Himelman RB, Schiller NB. Noninvasive estimation of right atrial pressure from the inspiratory collapse of the inferior vena cava. *Am J Cardiol* 1990;66:493-6.
37. Nagueh SF, Kopelen HA, Zoghbi WA. Relation of mean right atrial pressure to echocardiographic and Doppler parameters of right atrial and right ventricular function. *Circulation* 1996;93:1160-9.
38. Ommen SR, Nishimura RA, Hurrell DG, Klarich KW. Assessment of right atrial pressure with 2-dimensional and Doppler echocardiography: a simultaneous catheterization and echocardiographic study. *Mayo Clin Proc* 2000;75:24-9.
39. Himelman RB, Stulbarg MS, Lee E, Kuecherer HF, Schiller NB. Noninvasive evaluation of pulmonary artery systolic pressures during dynamic exercise by saline-enhanced Doppler echocardiography. *Am Heart J* 1990;119:685-8.
40. Hatle L, Brubakk A, Tromsdal A, Angelsen B. Noninvasive assessment of pressure drop in mitral stenosis by Doppler ultrasound. *Br Heart J* 1978;40:131-40.
41. Hatle L, Angelsen BA, Tromsdal A. Non-invasive assessment of aortic stenosis by Doppler ultrasound. *Br Heart J* 1980;43:284-92.
42. Currie PJ, Seward JB, Reeder GS, Vlietstra RE, Bresnahan DR, Bresnahan JF, et al. Continuous-wave Doppler echocardiographic assessment of severity of calcific aortic stenosis: a simultaneous Doppler-catheter correlative study in 100 adult patients. *Circulation* 1985;71:1162-9.
43. Currie PJ, Hagler DJ, Seward JB, Reeder GS, Fyfe DA, Bove AA, et al. Instantaneous pressure gradient: a simultaneous Doppler and dual catheter correlative study. *J Am Coll Cardiol* 1986;7:800-6.
44. Skjaerpe T, Hegrenaes L, Hatle L. Noninvasive estimation of valve area in patients with aortic stenosis by Doppler ultrasound and two-dimensional echocardiography. *Circulation* 1985;72:810-8.
45. Otto CM, Pearlman AS, Comess KA, Reamer RP, Janko CL, Huntsman LL. Determination of the stenotic aortic valve area in adults using Doppler echocardiography. *J Am Coll Cardiol* 1986;7:509-17.
46. Hatle L, Angelsen B, Tromsdal A. Noninvasive assessment of atrioventricular pressure half-time by Doppler ultrasound. *Circulation* 1979;60:1096-104.
47. Stamm RB, Martin RP. Quantification of pressure gradients across stenotic valves by Doppler ultrasound. *J Am Coll Cardiol* 1983;2:707-18.
48. Smith MD, Handshoe R, Handshoe S, Kwan OL, DeMaria AN. Comparative accuracy of two-dimensional echocardiography and Doppler pressure half-time methods in assessing severity of mitral stenosis in patients with and without prior commissurotomy. *Circulation* 1986;73:100-7.
49. Flachskampf FA, Weyman AE, Gillam L, Liu CM, Abascal VM, Thomas JD. Aortic regurgitation shortens Doppler pressure half-time in mitral stenosis: clinical evidence, in vitro simulation and theoretic analysis. *J Am Coll Cardiol* 1990;16:396-404.
50. Karp K, Teien D, Bjerle P, Eriksson P. Reassessment of valve area determinations in mitral stenosis by the pressure half-time method: impact of left ventricular stiffness and peak diastolic pressure difference. *J Am Coll Cardiol* 1989;13:594-9.
51. Loyd D, Ask P, Wranne B. Pressure half-time does not always predict mitral valve area correctly. *J Am Soc Echocardiogr* 1988;1:313-21.
52. Rokey R, Sterling LL, Zoghbi WA, Sartori MP, Limacher MC, Kuo LC, et al. Determination of regurgitant fraction in isolated mitral or aortic regurgitation by pulsed Doppler two-dimensional echocardiography. *J Am Coll Cardiol* 1986;7:1273-8.

53. Enriquez-Sarano M, Seward JB, Bailey KR, Tajik AJ. Effective regurgitant orifice area: a noninvasive Doppler development of an old hemodynamic concept. *J Am Coll Cardiol* 1994;23:443-51.
54. Teague SM, Heinsimer JA, Anderson JL, Sublett K, Olson EG, Voyles WF, et al. Quantification of aortic regurgitation utilizing continuous wave Doppler ultrasound. *J Am Coll Cardiol* 1986;8:592-9.
55. Chen CG, Thomas JD, Anconina J, Harrigan P, Mueller L, Picard MH, et al. Impact of impinging wall jet on color Doppler quantification of mitral regurgitation. *Circulation* 1991;84:712-20.
56. Mele D, Vandervoort P, Palacios I, Rivera JM, Dinsmore RE, Schwammenthal E, et al. Proximal jet size by Doppler color flow mapping predicts severity of mitral regurgitation: clinical studies. *Circulation* 1995;91:746-54.
57. Hall SA, Brickner ME, Willett DL, Irani WN, Afridi I, Grayburn PA. Assessment of mitral regurgitation severity by Doppler color flow mapping of the vena contracta [comments]. *Circulation* 1997;95:636-42.
58. Perry GL, Helmcke F, Nanda NC, Byarel C, Soto B. Evaluation of aortic insufficiency by Doppler color flow mapping. *J Am Coll Cardiol* 1987;9:952-9.
59. Pu M, Vandervoort PM, Griffin BP, Leung DY, Stewart WJ, Cosgrove DM, et al. Quantification of mitral regurgitation by the proximal convergence method using transesophageal echocardiography: clinical validation of a geometric correction for proximal flow constraint. *Circulation* 1995;92:2169-77.
60. Schwammenthal E, Chen C, Benning F, Block M, Breithardt G, Levine RA. Dynamics of mitral regurgitant flow and orifice area: physiologic application of the proximal flow convergence method: clinical data and experimental testing. *Circulation* 1994;90:307-22.
61. Enriquez-Sarano M, Miller FA Jr, Hayes SN, Bailey KR, Tajik AJ, Seward JB. Effective mitral regurgitant orifice area: clinical use and pitfalls of the proximal isovelocity surface area method. *J Am Coll Cardiol* 1995;25:703-9.
62. Utsunomiya T, Doshi R, Patel D, Mehta K, Nguyen D, Henry WL, et al. Calculation of volume flow rate by the proximal isovelocity surface area method: simplified approach using color Doppler zero baseline shift. *J Am Coll Cardiol* 1993;22:277-82.
63. Dujardin KS, Enriquez-Sarano M, Bailey KR, Nishimura RA, Seward JB, Tajik AJ. Grading of mitral regurgitation by quantitative Doppler echocardiography: calibration by left ventricular angiography in routine clinical practice. *Circulation* 1997;96:3409-15.
64. Reisner SA, Meltzer RS. Normal values of prosthetic valve Doppler echocardiographic parameters: a review. *J Am Soc Echocardiogr* 1988;1:201-10.
65. Chafizadeh ER, Zoghbi WA. Doppler echocardiographic assessment of the St. Jude Medical prosthetic valve in the aortic position using the continuity equation. *Circulation* 1991;83:213-23.
66. Burstow DJ, Nishimura RA, Bailey KR, Reeder GS, Holmes DR Jr, Seward JB, et al. Continuous wave Doppler echocardiographic measurement of prosthetic valve gradients: a simultaneous Doppler-catheter correlative study. *Circulation* 1989;80:504-14.
67. Baumgartner H, Khan S, DeRobertis M, Czer L, Maurer G. Discrepancies between Doppler and catheter gradients in aortic prosthetic valves in vitro: a manifestation of localized gradients and pressure recovery. *Circulation* 1990;82:1467-75.
68. Baumgartner H, Khan S, DeRobertis M, Czer L, Maurer G. Effect of prosthetic aortic valve design on the Doppler-catheter gradient correlation: an in vitro study of normal St. Jude, Medtronic-Hall, Starr-Edwards and Hancock valves. *J Am Coll Cardiol* 1992;19:324-32.
69. Pibarot P, Honos GN, Durand LG, Dumesnil JG. Substitution of left ventricular outflow tract diameter with prosthesis size is inadequate for calculation of the aortic prosthetic valve area by the continuity equation. *J Am Soc Echocardiogr* 1995;8:511-7.
70. Chambers JB. Mitral pressure half-time: is it a valid measure of orifice area in artificial heart valves? [review]. *J Heart Valve Dis* 1993;2:571-7.
71. Dumesnil JG, Honos GN, Lemieux M, Beauchemin J. Validation and applications of mitral prosthetic valvular areas calculated by Doppler echocardiography. *Am J Cardiol* 1990;65:1443-8.
72. Bitar JN, Lechin ME, Salazar G, Zoghbi WA. Doppler echocardiographic assessment with the continuity equation of St. Jude Medical mechanical prostheses in the mitral valve position [published erratum appears in *Am J Cardiol* 1995;76(8):642]. *Am J Cardiol* 1995;76:287-93.
73. Mohr-Kahaly S, Kupferwasser I, Erbel R, Oelert H, Meyer J. Regurgitant flow in apparently normal valve prostheses: improved detection and semiquantitative analysis by transesophageal two-dimensional color-coded Doppler echocardiography. *J Am Soc Echocardiogr* 1990;3:187-95.
74. Flachskampf FA, O'Shea JP, Griffin BP, Guerrero L, Weyman AE, Thomas JD. Patterns of normal transvalvular regurgitation in mechanical valve prostheses. *J Am Coll Cardiol* 1991;18:1493-8.
75. Daniel LB, Grigg LE, Weisel RD, Rakowski H. Comparison of transthoracic and transesophageal assessment of prosthetic valve dysfunction. *Echocardiography* 1990;7:83-95.
76. Khandheria BK, Seward JB, Oh JK, Freeman WK, Nichols BA, Sinak LJ, et al. Value and limitations of transesophageal echocardiography in assessment of mitral valve prostheses. *Circulation* 1991;83:1956-68.
77. Olmos L, Salazar G, Barbetseas J, Quiñones MA, Zoghbi WA. Usefulness of transthoracic echocardiography in detecting significant prosthetic mitral valve regurgitation. *Am J Cardiol* 1999;83:199-205.

GLOSSARY OF TERMS

Aliasing: Ambiguous frequencies (or velocities) caused by frequencies exceeding the PRF sampling (Nyquist) limit with PW Doppler. The high velocities "wrap around" and are displayed as negative velocities.

Amplitude: The intensity of the backscatter echoes reflected off the moving blood cells and displayed in gray scale. It reflects the number of red blood cells moving at a given velocity in a given time.

Baseline shift: Repositioning of the zero flow velocity line to the forward or reversed channels to overcome aliasing. Also referred as zero shift.

Bernoulli Equation: An equation that relates the instantaneous pressure drop across a discrete steno-

sis to convective acceleration, viscous forces, and early phasic acceleration. The latter 2 factors are usually neglected in the "modified" equation ($4V^2$).

Carrier frequency: The frequency emitted by the transducer.

Continuity equation: Principle of the conservation of mass in which the flow volume proximally to a valve equals the distal flow volume. Because flow = area (A) \times velocity (V), it follows that $A_1 \times V_1 = A_2 \times V_2$.

Continuous wave (CW) Doppler: A method to measure Doppler velocity with a transducer incorporating 2 ultrasound crystals (or array of crystals). One constantly transmits a selected ultrasound frequency, and the other constantly receives frequency shifts backscattered from red blood cells in motion. High-flow velocities can be recorded without aliasing, although depth localization is not possible.

Deceleration time: The time duration (in milliseconds) of the decrease from peak flow velocity to the zero baseline.

Diameter: The maximal linear measurement (in centimeters) of a circle.

Diastolic filling period: The duration of flow velocity from atrioventricular valve opening to closure.

Doppler equation: A mathematical equation that relates the observed frequency shift (ΔF) to the velocity of blood cells (V), the carrier frequency (F_0), the cosine of the angle theta (θ), and the speed of sound in soft tissue ($c = 1540$ m/s). The Doppler equation is $\Delta F = (V \times 2 F_0 \times \cos \theta) / c$.

Ejection time: The duration of flow from semilunar valve opening to closure.

Flow convergence region: The region proximal to a flow orifice in which flow streamlines converge, thereby creating "shells" of progressive flow acceleration. Isovelocity areas can be indicated by aliasing boundaries.

Flow profile: A spatial plot of velocity distribution across a vessel diameter that can be described as parabolic, flat, or irregular.

Frequency shift: The difference between transmitted and received ultrasound frequency. It is directly proportional to the velocity of blood flow as stated in the Doppler equation.

Gradient: The pressure drop or pressure difference across any restrictive orifice.

Hertz: A unit of frequency equal to one cycle per second; kilohertz (KHz) = 1000 hertz, and megahertz = 1 million hertz.

High pulse repetition frequency (PRF) Doppler: A method of achieving high sampling rates;

multiple pulses and their return signals from within the heart are present at any one point in time, and Doppler shifts along the beam are summed along sample volume depths that are multiples of the initial sample volume depth to give a single output.

Isovolumic contraction: The time period (in milliseconds) between atrioventricular valve closure and semilunar valve opening.

Jet: High-velocity flow signal in or downstream from a restrictive orifice.

Laminar flow: A flow state in which blood cells are moving in a uniform direction and with organized distribution of velocities across the flow area.

Mean velocity: The mean (average) of measured spectral shifts over a specific period within a given sample site.

Mirroring: An artifact of spectral display resulting in the inability of the spectrum analyzer to separate forward and reverse Doppler signals. The stronger signals are displayed in mirror-like fashion from the zero baseline in the opposite channel. Also called signal "cross talk."

Modal velocity: The mode in the frequency analysis of a signal is the frequency component that contains the most energy. In display of the Doppler frequency spectrum, the mode corresponds to the brightest (or darkest) display points of the individual spectra and represents the velocity component that is most commonly encountered among the various moving reflectors.

Nyquist limit: The highest Doppler shift frequency that can be measured. Equal to one half the pulse repetition frequency.

Pressure half time: The time (in milliseconds) that it takes for the maximal pressure gradient to decrease by one half.

Pulse repetition frequency (PRF): The rate at which pulses of ultrasound energy are transmitted.

Pulsed-wave (PW) Doppler: A method of Doppler interrogation that uses specific time delays to assess the Doppler shifts within a discrete region along the path of the sound beam.

Sample volume: The specific 3-dimensional site in which Doppler velocities are interrogated.

Sample volume width: The lateral and azimuthal dimensions of the PW Doppler sample volume, which depends on beam characteristics.

Sample volume length: The axial size of the PW Doppler sample volume.

Spectral analysis: A display of the Doppler shift frequency components over time. Frequency or

velocity is displayed in the Y-axis, time in the X-axis, and amplitude in gray scale.

Spectral broadening: An increase in the number of frequency components in a PW Doppler signal; an indicator of a disorganized flow pattern or high-velocity flow signal aliasing.

Velocity-time integral (VTI): Integral of the velocity over time.

Turbulent flow: Nonlaminar unstable blood flow in which the kinetic energy of flow creates vortices of differing velocities and direction.

Vena contracta: Smallest area of flow in or downstream from a restrictive orifice.

Wall filter: A control that rejects echocardiographic information from low-velocity reflectors such as wall motion.